

The Cases

SCLERAL LENS CASE REPORT SERIES

# Scleral Lens Case Report Series



BEYOND THE CORNEAL BORDERS


EDITOR: EEF VAN DER WORP

## Beyond the corneal borders

INDICATIONS · FITTING · MANAGEMENT & PROBLEM SOLVING



# Scleral Lens Case Report Series



## Beyond the corneal borders

INDICATIONS · FITTING · MANAGEMENT & PROBLEM SOLVING

# Contents

About the authors

4

Introduction

6

## Scleral Lens Case Report Series

## Indications

7

<b>Case 1</b>	Keratoconus, intrastromal rings and corneal crosslinking	8
<b>Case 2</b>	Keratoglobus	9
<b>Case 3</b>	Double LASIK treatment	10
<b>Case 4</b>	Radial keratectomy & corneal 'bridging' with a scleral lens	11
<b>Case 5</b>	Scleral Lenses for high hypermetropia	12
<b>Case 6</b>	Unilateral corneal perforation due to ocular trauma	13
<b>Case 7</b>	Herpes simplex infection	14
<b>Case 8</b>	Corneal dystrophy & scleral lens wear	15
<b>Case 9</b>	LASEK and dry eye	16
<b>Case 10</b>	Keratitis sicca	17

## Scleral Lens Case Report Series

## Lens fit

19

<b>Case 11</b>	Penetrating keratoplasty, corneal clearance & conjunctival 'sinking'	20
<b>Case 12</b>	Keratoconus, stromal rings & the importance of sufficient corneal clearance	21
<b>Case 13</b>	Progressive corneal ectasia	22
<b>Case 14</b>	Scleral lens fitting and corneal crosslinking	24
<b>Case 15</b>	Toric scleral lens in a keratoconus patient	25
<b>Case 16</b>	Herpes Keratitis & quadrant specific scleral lenses	26
<b>Case 17</b>	Keratoconus & the potential need for supplemental glasses	27
<b>Case 18</b>	Perforating corneal trauma & presbyopia	28
<b>Case 19</b>	Scleral lenses & low vision	29
<b>Case 20</b>	Hand-painted scleral lens	30

## Scleral Lens Case Report Series

## Management & Problem Solving

31

<b>Case 21</b>	Scleral lens refit, conjunctival redness/staining and haze in a PMD patient	32
<b>Case 22</b>	Keratoconus, deep anterior lamellar keratoplasty & allergic conjunctivitis	34
<b>Case 23</b>	Keratoconus & the need for managing dry eye symptoms	36
<b>Case 24</b>	Vision improvement and blanching in a keratoconus patient	38
<b>Case 25</b>	Keratoconus, ptosis & the importance of compliance	39
<b>Case 26</b>	Keratoconus, metamorphopsia, hygiene	40
<b>Case 27</b>	Keratoconus & scleral lens over-wear	42
<b>Case 28</b>	Scleral lenses in the elderly patient	43
<b>Case 29</b>	Keratoconus, crosslinking & the importance of informing patients regarding post-op vision	44
<b>Case 30</b>	Keratoconus, keratoplasty & acute hydrops	45



# About the authors



**Marjolijn Bartels MD, PhD**, is a staff member at the department of Ophthalmology at the Deventer Hospital, the Netherlands and a fellow of the European Board of Ophthalmology (FEBO). She has specialized in the medical and surgical treatment of corneal pathology and refractive

surgery in the Erasmus MC, Rotterdam, the Netherlands, where she was a senior staff member until 2009. Her PhD thesis (2005) was entitled 'Ways to Improve (Visual) Outcome in Corneal Transplantation, Corneal Pathology and Astigmatism. She is a member of the European Society of Cataract and Refractive Surgeons and American Academy of Ophthalmology. She is a (co) author on several publications on corneal transplantation, corneal crosslinking and refractive/secondary lens implantations.



**Jaap van Blitterswijk** is a contact lens practitioner, designer and manufacturer. He completed his study in Optics, Optometry and Contact Lenses in Rotterdam (NL). He founded the 'LENS' practices, with satellite locations in several hospitals. Jaap also founded Microlens Contactlens

Technology, a large innovative Dutch contact lens developing and manufacturing company. In practice Jaap is active in the medical applications of contact lenses. In manufacturing he is involved in the development of contact lens systems. Furthermore, Jaap spends lot of time educating on specialty lens fittings.



**Koen Brands** has worked as an optician in different settings for eight years. Since 2007 he has worked as an ophthalmologists' assistant (TOA). Since 2009 he has been affiliated with St. Elisabeth Hospital in Tilburg (NL), working as a TOA and a contact lens specialist. He began fitting scleral lenses in late 2010. Scleral lens indications

in his practice are mostly related to dry eye syndrome, keratoconus and irregular corneas due to trauma. Scleral lens fitting can be challenging, but very successful and is especially beneficial to the patients in his practice.



**Jean Claude Delcourt** is a contact lens practitioner at the department of Ophthalmology at the University of Liege, Belgium (BE). He is specialized in the fitting of lenses for the irregular corneas. He also specialized in electrophysiology.



**Bernard Duchesne MD, PhD** is a senior staff member at the department of Ophthalmology at the University of Liège, Belgium (BE) and medical director of the Liège Eye Bank. In 1995-1996, he achieved a research fellowship at the Bascom Palmer Eye Institute, Miami, Florida, USA. The topic

of his PhD thesis was the use of amniotic membrane for ocular surface reconstruction. He is a cornea and ocular surface specialist (medical and surgical). Member of several international society (AAO, EEBa, Cornea, Eucornea, SBO-BOG, Phi Beta Delta Alumni etc.) He is involved in keratoprosthesis surgery such as Boston KPro and Modified osteo-odonto keratoprosthesis.



**Chrétien Frambach** started his career as a teacher at a primary school. After four years of teaching, he changed his profession and became an optician and later an optometrist for which he graduated at the Hogeschool Utrecht (NL) in 2003. He started an optometric practice and

has worked as a part-time practice instructor at the school of optometry in Utrecht. Since 2004 he has been a member of the national board of examiners of contact lenses in the Netherlands. For the last four years he has worked at Oculenti specialty contact lens practice in the Rotterdam Eye Hospital (NL). This inspirational environment, where optometry students like to come and visit, demands great variability in contact lens options for a variety of patients.



**Carina Koppen MD**, is a senior staff member at the department of Ophthalmology at the University Hospital Antwerp, Belgium (BE) and a fellow of the European Board of Ophthalmology (FEBO). She specializes in the medical and surgical treatment of ocular surface and anterior

segment disease. The treatment of keratoconus and corneal crosslinking are the topics of her PhD thesis. As a member of the European Society of Cataract and Refractive Surgeons and EuCornea, she has presented several papers and organized instructional courses on keratoconus, contact lenses and corneal crosslinking. Recently she was elected Secretary-General of the European Contact Lens Society of Ophthalmologists.



**Inge Leysen** obtained her medical degree at the University of Antwerp (BE) in 2004. She finished her training in Ophthalmology at the Antwerp University Hospital in 2009. She still works part time in this hospital as a member of the medical staff of the ophthalmology department.

Fields of interest include cornea and contact lenses as well as oculoplastic surgery. She has been fitting corneal and scleral contact lenses since 2009 in cooperation with other ophthalmologists and optometrists. She also works part-time as a general ophthalmologist in a private practice.




**Leon Meijboom** received his optics training at Zadkine College in Rotterdam (NL) and got his optometry degree at the Hogeschool Utrecht (HU) in the Netherlands, where he graduated in 1997. He completed a four-month optometric internship at the University of Waterloo in

Canada and worked as a part-time practice instructor at the HU for 2 years in the clinical optometry department. He was a member of the editorial staff of Visus (the Dutch Journal of Optometry) for 10 years. Since 1997 he has worked as an optometrist at a large contact lens practice, LENS, in Utrecht (NL) where he has been working with scleral lenses since 2005.



**Cristian Mertz** got his optometry degree at the Hogeschool Utrecht (HU), where he graduated in 2009. After that he worked as an optometrist at a large contact lens practice, LENS, in Utrecht (NL). He has also been based at the hospital practice in Deventer hospital (NL) since

late 2010, where his main specialty is fitting medically indicated contact lenses such as scleral and hybrid lenses. In addition, Cristian is involved in the development of contact lenses and giving seminars for the Microlens Contactlens Technology company.



**Cor van Mil** has worked in several ophthalmic centers and practices as a contact lens practitioner since 1980 in The Netherlands. He graduated as an optometrist from the Hogeschool Utrecht (NL). His focus is on the therapeutic use of contact lenses. Even after many years of experience in the

field of contact lenses, he feels that there are still many new challenges for further development and new applications of all types of contact lenses. Cor has published several papers in the international peer reviewed journals on specialty contact lens-related topics. He is currently working at the Ophthalmic Medical Centre, Zaandam, (NL).



**Jan Pauwels**, completed his education as an optician/optometrist in 2006 in Brussels (BE). He worked at different optical practices before starting his own contact lens practice. Currently, he is the owner of Lens Optical Technology, which consists of 10 different practices in Belgium including three

university hospitals: UZA Antwerp, UZG Gent and CHU Liège. He specializes in fitting contact lenses on irregular corneas and has fit hundreds of patients with scleral lenses in the last year alone. He is a clinical investigator for a number of companies and is involved in research and development of new scleral lens devices.



**Ed Smit**. After finishing his study in Optics, Optometry and Contact Lenses in Rotterdam (NL) in 1977, Ed worked as an optician, later specializing in contact lenses and low vision. In 1999, he graduated from the Hogeschool Utrecht, school of optometry (Utrecht, NL). He is currently a board member of

the Dutch contact lens association ANVC. He also is a board member of the section on low vision and scleral lenses of the NUVO (the Dutch organization for opticians). For the last few years he has helped develop a new scleral lens design and educated many colleagues about the advantages and disadvantages of these lenses. For 30 years now he has worked as an optometrist in a general hospital and runs his own scleral lenses and low vision practice.

# Introduction

Large diameter contact lenses that have their resting point beyond the corneal borders are believed to be among the best vision correction options for irregular corneas; they can postpone or even prevent surgical intervention as well as decrease the risk of corneal scarring. For true clearance of the cornea, without any mechanical involvement, it seems advised to avoid contact between the lens and the cornea by bridging over it. A few years ago, only a handful of very specialized lens fitters around the world were capable of fitting scleral lenses successfully, and only a few manufacturers were making scleral lens designs in their arsenal. Improved manufacturing processes allow for better design, make lenses more reproducible and decrease costs, which combined with better lens materials has contributed to better ocular health, longer wearing time and ease of lens fit. This, in return, has broadened up the indication range for scleral lens fitting. But scleral lens fitting is still in its infancy, and this scleral lens case report series will share and discuss knowledge gained by practitioners who regularly work with these lenses.

Editing and writing this book has been a very educational experience for me. Working with all of these experts from the scleral lens arena who work with scleral lens patients on a very regular basis – some of them for decades – really taught me a lot about this modality. It is a modality that is new to many of us, which makes it extremely helpful to have primary access to the knowledge and experience of these practitioners, and to have that channeled into a practical case report series for fellow practitioners. This case report series is not intended to be a complete overview of all the topics that are relevant for scleral lens fitting: practitioners simply sent in the case reports they thought were good educational material, which we then evaluated, selected, edited and finally published.

If one thing has become clear to me while editing this book, it must be that scleral lens fitting truly is multi-tasking, and I admire anyone involved in this. Not only do practitioners need to have a good, basic background in lens fitting, understanding sagittal heights and the interaction between the different parameters, but they also need a good knowledge base and confidence in corneal physiology, understanding basic concepts such as oxygen delivery to the cornea and the consequences of hypoxia, for instance. In addition, practitioners need to be well educated and experienced regarding a wide variety of corneal pathology, including primary and secondary ectasia and ocular surface disease (in all its complexity), but also regarding corneal dystrophies and degenerations. In addition, patient management may be one of the key elements in scleral lens practice, as chapter 3 in this case report series illustrates. A technically successful lens fit alone is not sufficient for successful scleral lens wear. Several factors, including hygiene, proper lens care, good instructions and managing lens handling issues, play a crucial role in this process.

What amazed me most about the cases presented here is the significant impact that these lenses can have on people's lives. At the same time, the modality is still relatively unknown to many practitioners. It is in the best interest of the patient that more practitioners become familiar with this modality so they can serve patients with the best optical correction available. This may include scleral lenses, either to refer to specialty clinics or to get involved in fitting them. I sincerely hope that this book can serve as a contribution to understanding the challenges as well as the great benefits that scleral lenses can have.

Eef van der Worp



**Eef van der Worp**  
Editor

Eef van der Worp is an educator and researcher. He received his optics degree in Rotterdam in 1989 and his optometry degree in 1993 from the Hogeschool Utrecht in the Netherlands (NL), where he later served as a head of the contact lens department for over eight years. He received his PhD degree from the University of Maastricht (NL) in 2008. He is a fellow of the AAO, IACLE, BCLA and the SLS. He is an associate researcher at the University of Maastricht, a visiting scientist at Manchester University (Manchester, UK), adjunct Professor at the University of Montreal College of Optometry (CA) and adjunct assistant Professor at Pacific University College of Optometry (Oregon, USA). He lectures extensively worldwide and resides both in Washington, DC (USA) and Amsterdam (NL).

# Indications

Correcting the irregular cornea to restore vision is the main indication for fitting scleral lenses. The largest segment in the irregular cornea category is corneal ectasia, which can be subdivided into two groups. First is the primary corneal ectasia group, which includes conditions such as keratoconus, keratoglobus and pellucid marginal degeneration. Multiple examples of these will appear in this case report series.

The second ectasia group includes post-refractive surgery ectasia. Unsatisfying visual outcome after refractive surgery for a variety of reasons is an important – and growing – indication for scleral lens fitting. This group includes post-laser assisted in-situ keratomileusis (LASIK), post-laser assisted epithelial keratoplasty (LASEK), post-photorefractive keratectomy (PRK) and post-radial keratotomy (RK). A number of cases in this chapter will exemplify this, including a case of double LASIK treatment and a post-RK patient.


In some cases, patients with high refractive corrective errors who cannot be successfully fit with corneal lenses can benefit from scleral lenses. An example of a patient with high hypermetropic refractive error in this chapter will illustrate this.

Corneal transplants, especially the penetrating keratoplasty technique, often require a contact lens post-surgery to fully restore vision. A scleral lens may be indicated in many of these cases, as a number of cases will show in this book. Other irregular cornea indications with the primary goal to restore vision include post-trauma corneas. Eyes with significant scarring and severely irregular corneas due to trauma can often achieve excellent vision with scleral lenses – often to the surprise of both the patient and the practitioner. One of the cases in this chapter reports on a corneal perforation after trauma resulting in a large corneal scar in which scleral lenses improved the vision dramatically.

Corneal scars as a result of corneal infections, especially Herpes Simplex, are frequently indications for fitting scleral lenses, as one case in this chapter will illustrate. In addition, because of the decrease in corneal sensitivity in cases like this, these corneas can also develop ocular surface disease and trophic conditions, which scleral lenses can help manage.

Corneal degenerations or dystrophies, such as Terrien's marginal degeneration and Salzmann's nodular degeneration, are also indications for scleral lenses. One of the cases in this chapter reports on a map dot fingerprint dystrophy and posterior polymorphous dystrophy case.

Exposure keratitis/ocular surface disease patients have been shown to particularly benefit from scleral lenses because of the retention of a fluid reservoir behind the scleral lens. A case of dry eye that developed post-LASIK will be covered in this chapter. Sjögren's syndrome is a common scleral lens indication. Under this category also fall conditions such as persistent epithelial corneal defects, Steven's Johnson Syndrome, Graft Versus Host Disease, ocular cicatricial pemphigoid, neurotrophic corneal disease and atopic keratoconjunctivitis. One case in this series reports a severe keratitis sicca because of lagophthalmus as a result of a cranial nerve VII - facial paresis after a brain tumor as well as a ptosis. This shows that even in severely compromised corneas, scleral lenses can prove beneficial in creating a moist environment to nurture the cornea.





indication



keywords



Case



Gender: Male

Age: 41



discussion

# Keratoconus, intrastromal rings and corneal crosslinking

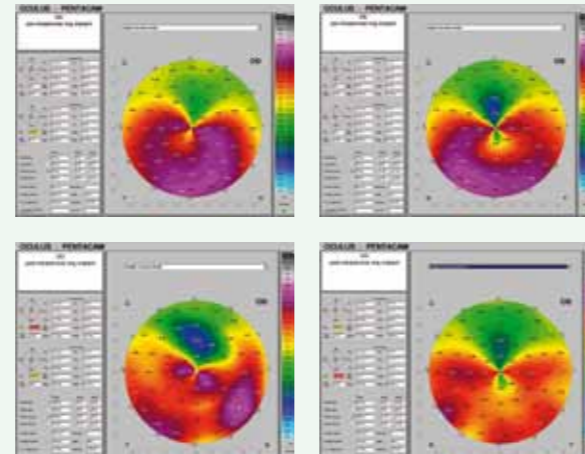
Jan Pauwels, Carina Koppen and Inge Leysen

Keratoconus | intrastromal rings | corneal crosslinking (CXL)

## Introduction

Keratoconus is the number one indication for scleral lenses, as is evident by the titles of several cases in this series of scleral lens case reports. However, to overcome the problems associated with keratoconus, many of the patients we see with keratoconus have undergone procedures such as intrastromal rings, corneal grafting or, more recently, corneal crosslinking (CXL). This case is a perfect illustration of that: a 41-year-old patient was first diagnosed with keratoconus 9 years ago. The keratoconus was progressive in nature, and in 2008 the patient underwent CXL to try to give the cornea more structure and rigidity, although this procedure is not designed to improve vision. In 2009, intrastromal rings were implanted to try to achieve a more optimal visual acuity and also because of reported ocular allergies of the patient and potential problems with contact lens wear. Unfortunately, his vision was still highly suboptimal after this procedure. At this point, scleral lenses were considered.

But the clearance was sufficient without any pressure and we will keep monitoring this (see slit lamp images of the lens in place with added fluorescein in the tear reservoir [with and without cobalt blue light] and with the intrastromal rings visible behind the lens).



## Subjective & objective findings

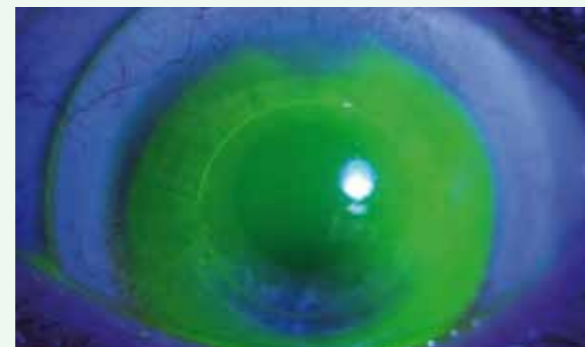
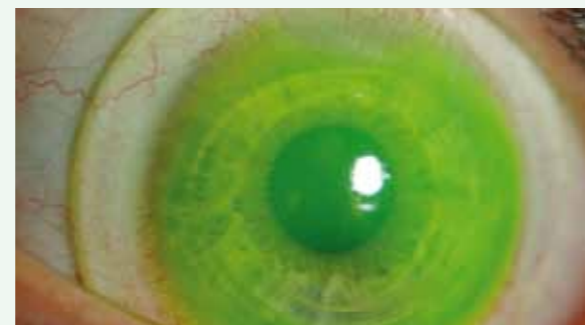
The 41-year-old male with keratoconus, status after CXL and intrastromal rings.

### Refraction:

VOD	S +0.50 C -7.00 @ 71	VA 0.5
VOS	S 0.00 C -2.50 @ 70	VA 0.4

**Corneal topography:** see Oculus Pentacam images, pre-intrastromal ring implant OD and OS (top) and post-intrastromal ring implant OD and OS (bottom).

**Slit lamp:** examination revealed clear corneas with intrastromal rings ODS.



© Photographs: University Hospital Antwerp (Belgium).

The first lenses ordered and dispensed after first inspection and assessment were:

### Mini Misa Scleral:

OD Vault	375/S+3.00/BCR 8.80/Ø 16.50/SC 13.5/LZ normal
OS Vault	375/S+2.25/BCR 7.80/Ø 16.50/SC 13.5/LZ normal

### Over-refraction:

VOD	S 0.00 C -1.00 @ 135	VA 0.9
VOS	S 0.00 C -1.00 @ 24	VA 0.9

### 3rd month follow up visit

The patient was very satisfied with his newly gained visual acuity. His wearing time was at least 10-13 hours a day. He used tear supplements for his dry eye symptoms.

Sometimes, when rubbing his eyes with the lenses in place, the lens would come in contact with the intrastromal rings.


## Summary & Discussion

This patient exhibits a classic case of keratoconus, with or without 'adjustments' such as CXL or intrastromal rings, in which the visual acuity with scleral lenses can be boosted – from 0.4 and 0.5 to 0.9 in each eye in this case. For many patients this could mean they will be able have normal working opportunities and functioning in society as well as being allowed driving a car. It is an important task for specialty lens practitioners to help these patients. All eye care

practitioners should be well informed about the significant improvements that scleral lenses can offer to some patients so they can either provide these lenses as an option to such patients or so they can refer such patients to an eye care practitioner who can do so. This case also illustrates that contact lenses should perhaps be tried first before refractive surgery procedures in many cases of keratoconus rather than the other way around.



indication



keywords



Case



Gender: Male

Age: 24



discussion

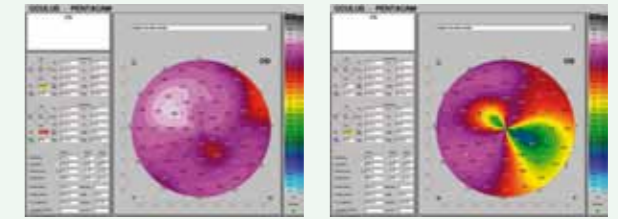
# Keratoglobus

Jan Pauwels, Carina Koppen and Inge Leysen

Keratoglobus | Penetrating Keratoplasty (PKP) | extreme scleral vault

## Introduction

This patient was diagnosed with bilateral advanced keratoglobus. OS had undergone a penetrating keratoplasty (PKP), but for OD the cornea was too thin to consider this. This proved to be a challenging case, in which we had to custom order two scleral lenses with very high vault.



## Subjective & objective findings

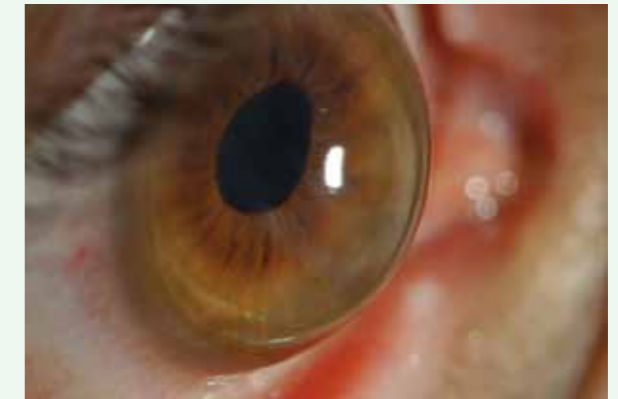The 24-year-old male with keratoglobus OD and a corneal graft after keratoglobus OS came for a scleral lens fit.

### Refraction:

VOD	<0.01	could not be improved
VOS	0.01	could not be improved

**Corneal topography:** see Oculus Pentacam images OD and OS.

**Slit lamp:** Examination revealed OD extreme corneal ectasia. The cornea was, despite the extreme shape and thinning, mostly clear with only some scarring seen inferiorly (see corneal slit lamp images – no lens). OS examination revealed a corneal graft with ectasia and no stitches, and also a clear cornea.



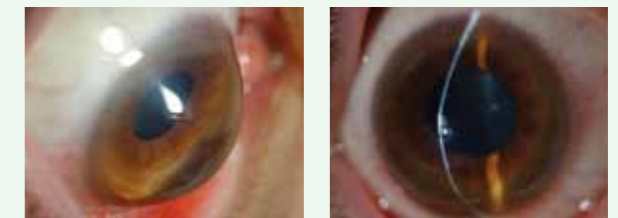The first lenses ordered and dispensed after first inspection and assessment were:

### Mini Misa Scleral:

OD Vault	5.25/S-4.00/BCR 7.80/Ø 16.5/SC 13.5/LZ wide
OS Vault	4.50/S-4.50/BCR 7.80/Ø 16.5/SC 13.5/LZ wide

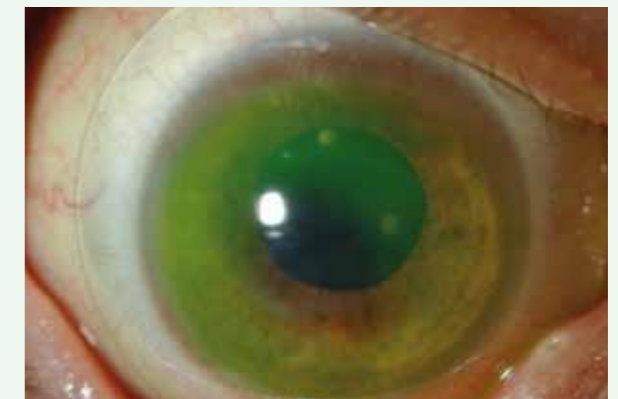### Over-refraction:

VOD	S 0.00	VA 0.5
VOS	S 0.00	VA 0.8



### 1 year follow up visit

The patient has been seen regularly over the last year, which was a necessity in the given circumstances and corneal condition. The right lens still, despite the extreme vault of the lens, was slightly touching the cornea, leading to slightly more discomfort on this eye compared to the left eye (see slit lamp image with lens in place) but without corneal staining. To increase the sagittal height of the lens even more was technically not possible at this point. The wearing time was acceptable though, with 8 hours of lens wear per day for the right eye and 14 hours for the left eye. We will keep monitoring him to see how he is doing and whether we can optimize the lens fit going forward.



© Photographs: University Hospital Antwerp (Belgium).

## Summary & Discussion

Keratoglobus is one of the three types of primary ectasia that also include keratoconus and pellucid marginal degeneration. Keratoglobus is a rare condition, in which basically the entire cornea from limbus to limbus bulges out. These are extreme difficult cases to fit with corneal lenses, and scleral lenses are almost by default the preferred option because they bridge over the entire cornea. However, as this case indicates, extremely high levels of vault may be necessary to achieve this in some patients.



indication



keywords

# Double LASIK treatment

Leon Meijboom

Post-LASIK (Laser-Assisted In Situ Keratomileusis) | flat corneal radii | oblate corneal shape | subconjunctival hemorrhage | lens suction | artificial tears

3 Case



Gender: Male

Age: 69

## Introduction

A 69-year-old white male underwent LASIK treatment in 2003 for a myopic correction. In 2004, a re-treatment was performed because the original treatment yielded insufficient results. After this second treatment, a myopic shift occurred with double (and distorted) vision in his left eye. He was occasionally wearing a corneal RGP lens for his left eye, with glasses to correct the remaining cylinder with good visual acuity. The disadvantage was that because of the flat radii and the oblate corneal shape, the lens did not fit properly and thus yielded comfort complaints and excessive lens movement. We advised a scleral lens fit to overcome these problems for the left eye in this patient.

## Subjective & objective findings

A 69-year-old patient underwent LASIK treatment eight years ago and re-treatment one year later. He suffers from double vision in his left eye, resulting in insufficient visual acuity with spectacle wear. The patient is healthy, uses no medication and is not allergic.

**Refraction:**  
VOD S +1.50 C -1.50 @ 120 VA 0.9  
VOS S + 4.50 C -0.25 @ 5 VA 0.3  
(patient reports double vision)

**Corneal topography:** see Topcon KR 8100PA topography image.

**Slit lamp:** Healthy cornea and adnexa. No staining. Tear meniscus and BUT are unremarkable.

Given the refraction, corneal radius and the complaints with the corneal lens, we advised fitting a (mini) scleral lens for his left eye. The right eye is well corrected by his glasses and he does not want to wear a lens on that eye.

The first lens ordered for his left eye and dispensed after first inspection and assessment was:

**Mini Misa Scleral:**  
Vault 3.00/S-4.75/BCR 9.50/Ø 16.50/SC 13.0/LZ Wide

## 1st follow up visit

The patient had been wearing the Misa lens for 1 week at this visit. He reported that the lens felt comfortable. Lens handling (inserting) was improving every day. He was taking the lens out of his eye after 4 hours of lens wear, leaving it off for half an hour and then re-inserting the lens for another 4 hours. At the end of the 4 hours the lens was causing a burning sensation. Vision with the lens was satisfactory.

**Over-refraction:**  
OS S 0.00 C -1.00 @ 95 VA 0.9

The lens was fitting rather flat centrally, which resulted in a central corneal touch, while mid-peripherally a small air bubble was seen (see slitlamp images top right).

A lens with a steeper central radius and a smaller landing zone was ordered:

**Mini Misa Scleral:**  
Vault 3.00/S-4.75/BCR 9.20/Ø 16.50/SC 13.5/LZ normal

## 2nd follow up visit

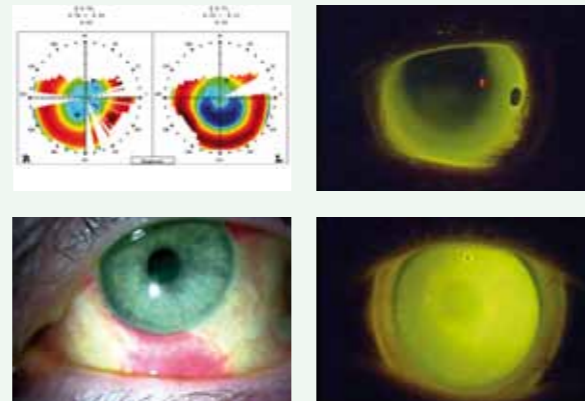
At this visit the patient presented with a red left eye after removal of the lens the night before. He reported no pain, photophobia or other symptoms other than a red eye. He was not wearing the lens at the time. A subconjunctival hemorrhage superior and inferior OS was evident upon slit lamp examination (see slitlamp images bottom left).

## 3rd follow up visit

After one week of wearing the new Mini Misa Scleral lens, comfort did improve but removing the lens was sometimes hard to do. The lens seemed suctioned onto the eye after 4 hours of lens wear. Visual acuity was good enough with the addition of his glasses (with the cylindrical correction), although not as good as with his corneal lens, he reported.

The Misa Scleral fit was improved (see slitlamp images bottom right). It was easy to manually rotate the lens and no blanching appeared upon slit lamp examination. The subconjunctival hemorrhage had disappeared. At the moment he is satisfied and no lens changes are needed. We advised him to insert a drop of an artificial tears supplement before lens removal to reduce the lens suction on the eye and scheduled a regular eye exam for after 3 months. A consult by phone was planned after 2 weeks to determine whether lens removal became easier by using the artificial tears.

As he is wearing glasses for the correction of his right eye, the cylindrical over refraction over the scleral lens can be added for his left eye to this prescription.



## Summary & Discussion

Given the increase in the number of eyes undergoing refractive surgery, the demand for contact lens fitting for post treatment will increase, too. This is because the desired correction is not always achieved and/or because of regression of the cornea over time. Another important factor is the possibility of a secondary corneal ectasia post refractive surgery.

Sometimes a reverse geometry lens may provide good results on these post refractive surgery eyes. But if this is not sufficient, fitting of a (mini) scleral lens can be a good alternative – as in this case. This case demonstrates that a scleral lens can be an excellent indication for an oblate shaped cornea, considering the centration and fitting problems that can arise with corneal lenses.



discussion

# Radial keratectomy corneal 'bridging' with a scleral lens

Jan Pauwels, Carina Koppen and Inge Leysen

Radial keratectomy (RK) | reverse geometry



indication



keywords

4 Case



Gender: Male

Age: 40

## Introduction

This case reports describes a patient who underwent radial keratectomy (RK) 25 years ago, when the procedure was still in its infancy. Unaided visual acuity OD was VA 0.6, and OS it was limited to 0.1. With correction the right eye reaches a VA 1.0, but OS does not exceed 0.6. Several RGP lenses had been tried to optimize his visual acuity, but the flat central corneal curvatures, creating an oblate corneal shape, make this a challenge. This is also referred to as a reverse geometry cornea, as the normal cornea is typically steeper in the center than in the periphery (called an oblate cornea). A reverse geometry corneal shape can result in poor RGP lens fits oftentimes with central pooling and central air bubbles.

## Subjective & objective findings

A 40-year-old male patient underwent RK 25 years ago ODS. The eight radial incisions/scars are visible with otherwise clear cornea. Visual acuity OD>OS. He complains of suboptimal vision.

**Refraction:**  
VOD S +4.00 C -4.00 @ 80 VA 0.6  
VOS sc VA<0.1  
Refraction does not provide any improvement.

**Corneal topography:** irregular cornea ODS (see Oculus Pentacam image OD and OS)

**Slit lamp:** radial incisions are visible, clear corneas (see slitlamp images, with and without lens)

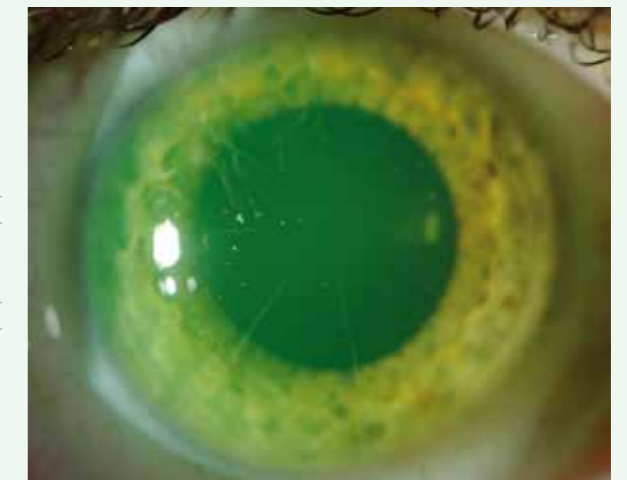
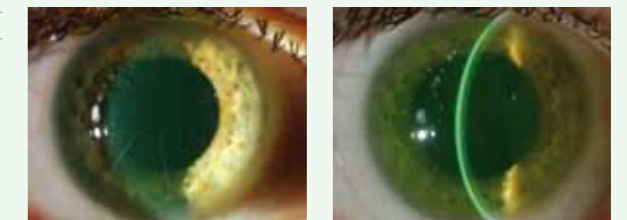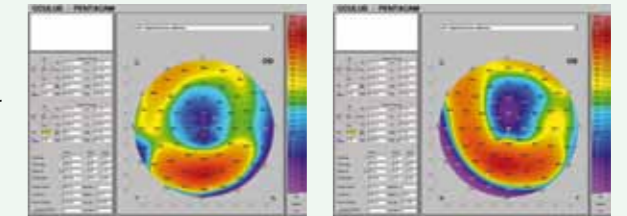
Because of the oblate corneal shape, a scleral lens was chosen that can bridge over the entire cornea and its irregularities.

The first lens ordered and dispensed after first inspection and assessment was:

**Mini Misa Scleral:**  
OD Vault 3.25/S-0.25/BCR 8.80/Ø 16.50/SC 13.5/LZ normal  
OS Vault 3.25/S-0.00/BCR 8.80/Ø 16.50/SC 13.5/LZ normal

**Over-refraction:**  
VOD S -0.75 VA 1.0  
VOS S 0.00 C -0.75 @ 170 VA 0.6

The visual acuity OS cannot be improved further. The reason for this is unclear, but in post-RK cases the visual acuity sometimes remains suboptimal due to severe corneal distortion.



© Photographs: University Hospital Antwerp (Belgium).

## Summary & Discussion

Even in severely irregular corneas, scleral lenses can be an exceptionally good option for correction. Because a scleral lens bridges over the entire cornea, the amount of irregularity on the cornea in essence becomes irrelevant. In this case of an oblate cornea in which there was significant corneal flattening centrally, it would be extremely difficult to fit a standard RGP or soft lens since the design of these lenses have the opposite shape. Both soft and RGP reverse geometry lens designs have been developed for this purpose – but

creating an optimal lens fit is usually still very challenging and demanding. The option of bridging over the cornea and creating a corneal clearance is probably most preferred, as the shape of the sclera in all of these challenging corneas is assumed to be standard and unchanged and is therefore not any more challenging than is a normal scleral lens fit.



discussion





indication



keywords

# Scleral lenses for high hypermetropia

Jan Pauwels, Carina Koppen and Inge Leysen

High hypermetropic refractive error | dusty work environment

5 Case

Gender: Male

Age: 25



discussion

## Introduction

A hyperopic prescription and a dusty work environment made it difficult to come up with a satisfying vision correction method for this young patient. He works for a roofing company, and heavy S+8.00 glasses were highly uncomfortable. RGP contact lenses have always given him problems, and because of significant corneal astigmatism, soft lenses were not preferred, either. We considered fitting him with scleral lenses.

## Subjective & objective findings

A 25-year-old male patient had hyperopic correction and was unsatisfied with glasses and corneal lenses.

● **Refraction:**

VOD	sc 0.1	S+8.50 C -4.50 @ 180	VA 0.7
VOS	sc 0.1	S+9.50 C -4.50 @ 170	VA 0.7

● **Corneal topography:** symmetric astigmatic patterns.

● **Slit lamp:** examination revealed clear corneas.

A toric scleral lens was chosen as the first scleral fits with standard lenses revealed a toric scleral shape. The first lenses ordered and dispensed after first inspection and assessment were:

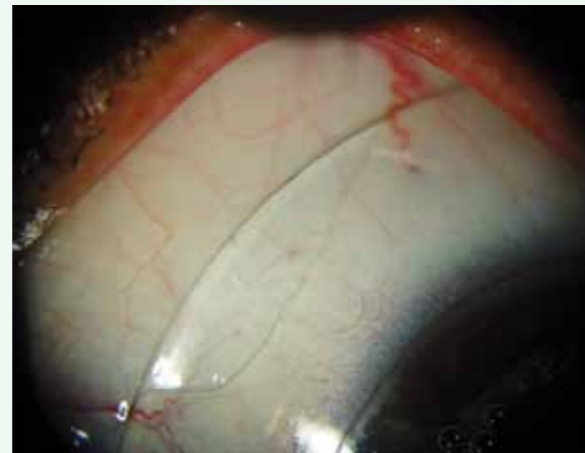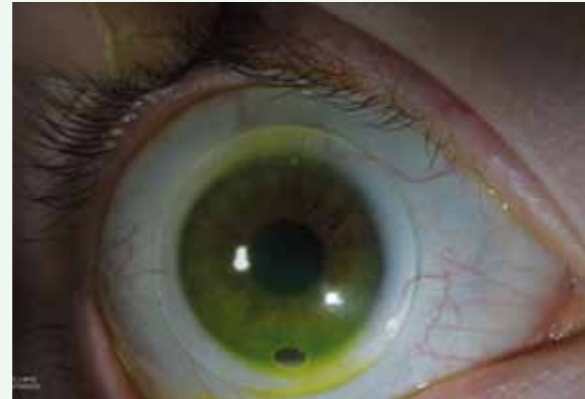**Mini Misa Scleral T:**  
 OD Vault 3.25/S+4.25/BCR7.80/Ø21.50/SC13.5-12.75/LZ normal  
 OS Vault 3.25/S+4.00/BCR7.80/Ø21.50/SC13.5-12.75/LZ normal

● **Over-refraction:**

VOD	S 0.00	VA 0.8
VOS	S 0.00	VA 0.8

## 3 month follow up visit

The patient was wearing his lenses for a minimum of 12 hours a day, at least during his working hours. Only over the weekends and in the evening did he wear his spectacles. Because this concerned a 'simple' ametropia indication for scleral lenses, alternating with spectacles was fine.



© Photographs: University Hospital Antwerp (Belgium).

## Summary & Discussion

The indication of this scleral lens fit differed from most other indications for scleral lenses, as illustrated in this scleral lens case series. All other indications had a pathology as the origin. This case proves that the indication range for scleral lens fitting is becoming broader. Up to fairly recently, scleral lenses were indicated mainly for extremely irregular and challenging corneas. But with the success of modern scleral lenses, including improvements in fitting technique, material and design, refractive problems such as high refractive errors (myopic and hyperopic) and corneal astigmatism – among many others – are eligible for scleral lenses.

Although an apparently straightforward case, because of the absence of pathology and normal eye shape, the first standard lens tried on this patient revealed a significant

toric scleral shape and a toric lens was required. Toric scleral shapes, as is illustrated here by a picture of an eye showing with the rule scleral astigmatism represented by the presence of fluorescein in the vertical meridian and a picture illustrating an eye where one quadrant lifts off of the sclera in an oblique meridian, are not uncommon. Results from the Pacific University Scleral Shape Study have revealed that on average, the temporal inferior section of the anterior sclera is the deepest, and the nasal section is the flattest. But a lot of individual variance is seen. More on toric scleral shapes and non-rotationally symmetric lenses later on in this scleral lens case report series.



indication



keywords

6 Case

Gender: Male

Age: 41



discussion

# Unilateral corneal perforation due to ocular trauma

Koen Brands

Trauma | perforation | central vertical corneal scar | binocular vision

## Introduction

This case report is regarding a 41-year-old male, OD status after trauma (corneal perforation due to an accident) with a central vertical corneal scar present. Our goal was to increase the visual acuity OD. The patient was experiencing vision loss in his right eye and his binocular vision was disturbed as a result.

## Subjective & objective findings

41-year-old male, status after trauma from falling and hitting his eye on a door handle was a corneal perforation OD. Otherwise, clear ocular history and general health.

● **Refraction:**

VOD	sc 0.05	S +14.50 C -4.25 @ 170 (auto-refraction)	VA 0.1
VOS	sc 0.8-	S -0.75 (auto-refraction)	VA 1.0

● **Corneal topography:** see Oculus Pentacam image.

● **Slit lamp:** There was a suture at 12 o'clock on the cornea (see slit lamp images - with and without scleral lens) and a central vertical scar was visible. The pupil OD was abnormal in size as a result of the trauma.

Given the vertical scar, the severe corneal irregularities and the low best corrected visual acuity OD, a scleral lens fit was considered for this eye. At this time, no correction for OS was considered.

The first lens was ordered and dispensed after first inspection and assessment as follows:

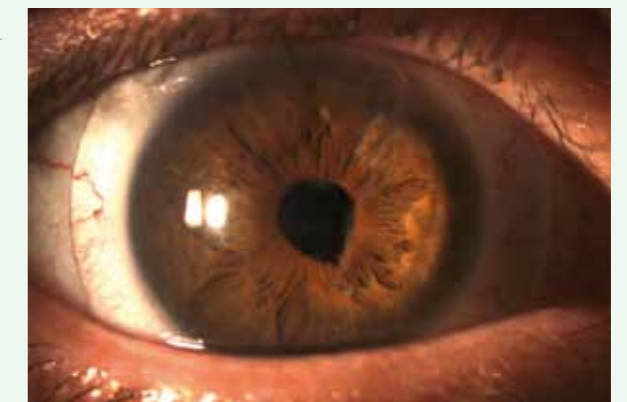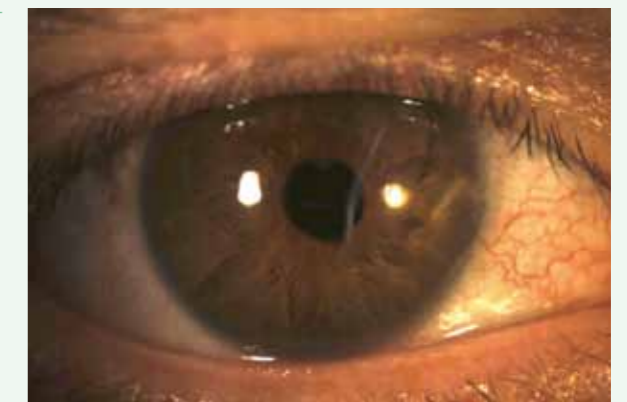
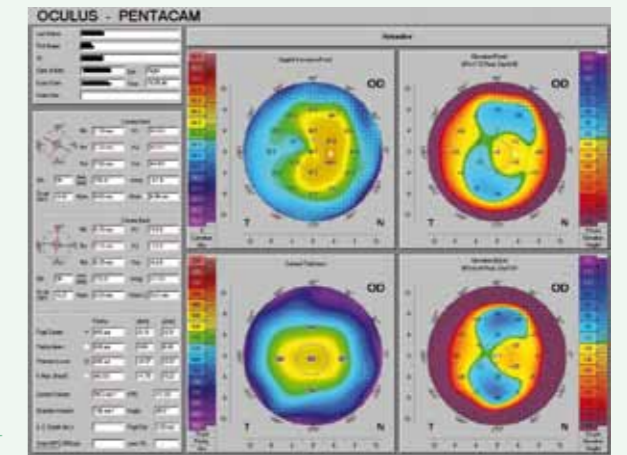
**Mini Misa Scleral:**  
 Vault 3.25/S +11.75/BCR 7.80/Ø 16.5/SC 13.5/LZ normal

Delivery and instruction went very well. Patient could remove and insert the lens without problems. Over-refraction after 4 hours of wearing time: VODcc 0.6- S + 2.25 VA 0.8-

Adjusted power of ordered lens prescription to S +14.00.

## 1st follow up visit

Patient was very satisfied and was experiencing normal binocular vision. Vision was improved and comfort was good: VODcc 0.8- S +0.25 VA 0.8-. Slit lamp examination revealed no blanching, with the cornea and conjunctiva in good health. Good lens centration was observed. We will see the patient again in six weeks for a regular check up.



## Summary & Discussion

The goal to increase the visual acuity OD to improve binocular vision after a corneal perforation was met in this patient by fitting his right eye with a Misa Mini scleral lens with a diameter of 16.5mm. His best corrected visual acuity OD with the initial refraction was 0.1, which improved to 0.8- with the scleral lens.

# Herpes simplex infection

Jan Pauwels, Carina Koppen and Inge Leysen

Corneal dystrophy | corneal herpes simplex infection | corneal scar

## Introduction

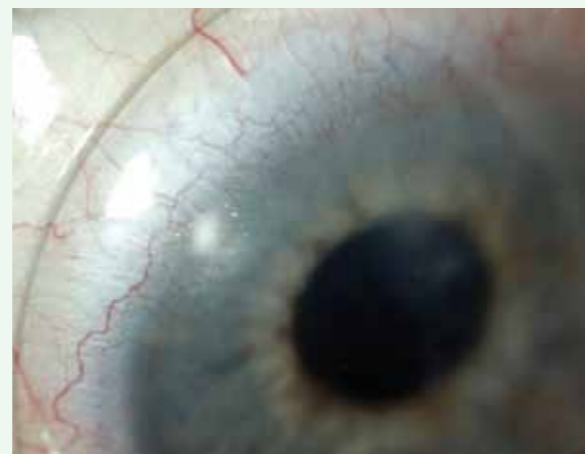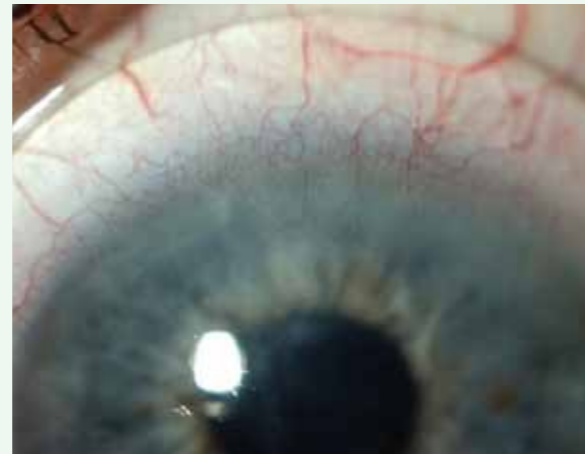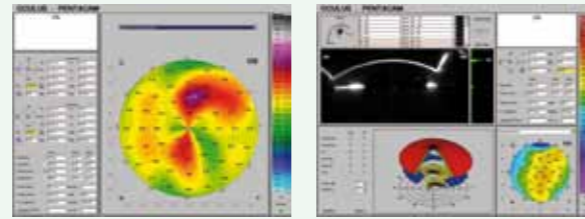
This patient developed a corneal Herpes Simplex infection OS, which resulted in a highly irregular scar on his cornea. Corneal scars, especially if caused by a Herpes Simplex infection, have proven to be a good indication for a scleral lens, as this case illustrates. No previous lens wear was reported.

## Subjective & objective findings

A 65-year-old male, status after Herpes Simplex infection OS.

- **Refraction:**

VOD	S +2.75 C -0.50 @ 65	VA 1.0
VOS	S +0.75 C -3.25 @ 133	VA 0.15
- **Corneal topography:** see Oculus Pentacam topography image OS
- **Slit lamp:** examination revealed a clear cornea OD, central scar OS with an irregular corneal surface. See Oculus Pentacam Scheimpflug image OS with localized thinning superior.



© Photographs: University Hospital Antwerp (Belgium).

The first lens ordered and dispensed OS after first inspection and assessment was:

**Mini Misa Scleral:**  
Vault 325/S-4.50/BCR 7.80/Ø16.50/SC 13.5/LZ Wide

- **Over-refraction:**

VOS	S +2.50	VA 0.5*
-----	---------	---------

\* The lens was purposely designed to create this over-refraction to match OD and to prevent anisometropia.

## 6th month follow up visit

The risk of recurrence of the latent Herpes virus on the cornea, possibly triggered by the stress of a new scleral lens fit, was a serious concern. The patient was monitored closely and checked regularly. The status after six months was that the patient was very satisfied. Visual acuity improved dramatically to 0.5, which was at an acceptable level for the patient and was sufficient enough to cancel a corneal transplant procedure that was planned for him originally.

## Summary & Discussion

Visual improvements of corneal scars, especially after Herpes Simplex infections, can be exceptionally good with scleral lenses. In this case, the measured VA was not outstanding, albeit a dramatic improvement over his BCVA with glasses. Nevertheless, the subjective vision was rated as good and certainly acceptable, up to the point that surgery can at least be postponed at this point.

In addition, because of the reduced corneal sensitivity in cases like this, these corneas can also develop ocular surface disease and trophic corneal conditions. Scleral lenses are

therefore an exceptionally good indication for Herpes Simplex corneal disease, as they can help alleviate these problems, too, in addition to improving vision.

# Corneal dystrophy & scleral lens wear

Cristian Mertz, Jaap van Blitterswijk, Marjolijn Bartels

Posterior polymorphous dystrophy | map dot fingerprint dystrophy | wearing time

## Introduction

This patient was diagnosed with posterior polymorphous corneal dystrophy in both eyes 20 years ago. Six months ago they also diagnosed him with map dot fingerprint dystrophy in both eyes. The condition of his cornea had caused a decrease in visual acuity. He was currently wearing no correction and he complained of suboptimal vision. The referring ophthalmologist wanted to know whether there would be an increase in visual acuity with scleral lenses.

## Subjective & objective findings

A 47-year-old white male was known to have posterior polymorphous dystrophy and recently Map Dot Fingerprint dystrophy. The last was decreasing his visual acuity. The patient was healthy, used no medications and had no allergies.

- **Refraction:**

OD	plano	VA 0.16
OS	-0.25 -1.25 @ 170	VA 0.5
- **Corneal topography:** see Microlens topographer images OD and OS (with keratometric overlay in mm).
- **Slit lamp:** OD=OS irregular epithelium with lines & dots (mainly central) and stromal opacities. There were some guttata.

Given the cornea irregularities, a scleral lens fit was considered for both eyes. The first pair of lenses ordered and dispensed after first inspection and assessment was:

**Misa Scleral:**  
OD Vault 3.25/S +2.00/BCR 8.30/Ø 18.5/SC 13.5/LZ normal  
OD Vault 3.50/S +2.50/BCR 8.30/Ø 18.5/SC 13.5/LZ normal

## 1st follow up visit

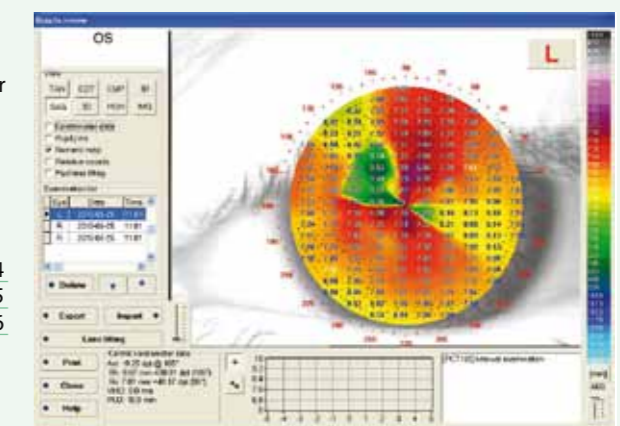
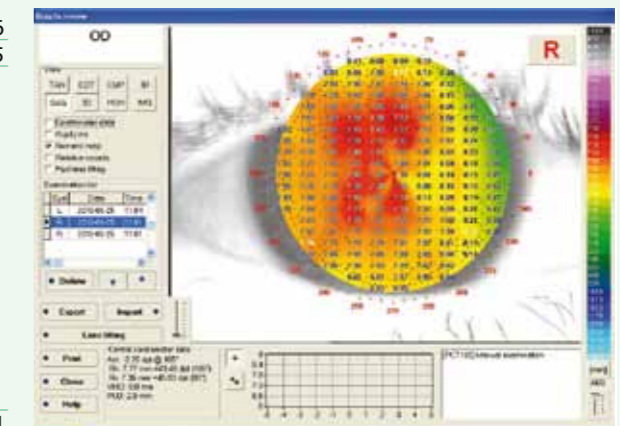
Upon arrival, the patient wasn't wearing the lenses because the drive to the hospital takes too long. It was not possible for the patient to wear the lenses for longer than 2 hours before his vision would decrease. Still, the patient was pleased with the result because within the first 2 hours the visibility was good and therefore he could function better.

- **Over-refraction:**

OD	cc	S 0.00	VA 0.4
OS	cc	S 0.00	VA 0.5
			VOD 0.6

The lenses felt comfortable and the lens fit looked good. Slit lamp examination revealed no blanching, with the conjunctiva in good health. It was not exactly clear whether the comfort problem was related to dryness or to deposits on the lenses.

The patient was going to continue to wear the lenses. It was important that he take out the lenses on schedule for cleaning with a mild, non-ionic cleaner before re-application. At the next follow-up visit in six weeks, the lenses needed to be worn for a longer period of time to determine what is causing the lens cloudiness.



## Summary & Discussion

Patients with epithelial dystrophies are sometimes difficult to help with corneal lenses. It is better not to touch the irregular and weak cornea with contact lenses. In some of these cases a scleral lens can be the solution, but in this case it is probably not possible for the patient to wear the lenses all day long. Still, the patient reported that the quality of life was improved with wearing the lenses, and the health of the eye was not compromised in any way. Therefore we will continue to search for a better outcome in terms of wearing time. This

is an important task for those of us in contact lens practice, especially since there are no conservative vision correction alternatives available for patients like this.



indication



keywords

# LASEK and dry eye

Cristian Mertz, Jaap van Blitterswijk, Marjolijn Bartels

Laser-Assisted Sub-Epithelial Keratectomy (LASEK) | dry eye | corneal haze.

## Introduction

A 37-year-old white female underwent LASEK treatment in 2008 for myopic correction. In 2009, a re-treatment was performed because a myopic shift occurred after the original treatment. After this second treatment, a myopic shift occurred again. She tried soft and RGP lenses, but because of dry eyes, the maximum wearing time was a few hours. For dry eye management she was using artificial tears: Oculotect (Novartis) and Celluvisc (Allergan). The ophthalmologist advised a scleral lens fitting to overcome the dry eye and remaining myopia.

## Subjective and objective findings

A 37-year-old patient underwent LASEK treatment 3 years ago and retreatment 2 years ago. She suffered from dry eyes and myopia. The patient was healthy, used no medications and had no allergies.

### Refraction:

OD	S -1.50	VA 1.0
OS	S -1.00 C -0.25 @ 180	VA 0.9

● **Corneal topography:** see Microlens topographer images OD and OS (with keratometric overlay in mm).

● **Slit lamp:** examination revealed ODS post-LASEK corneal haze, with low tear break-up time & low tear meniscus ODS.

Given her refraction, corneal radii and dry eye, a scleral lens fitting with a large tear reservoir for both eyes was advised.

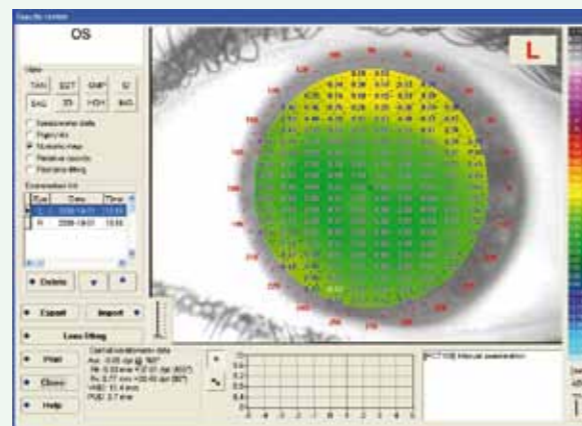
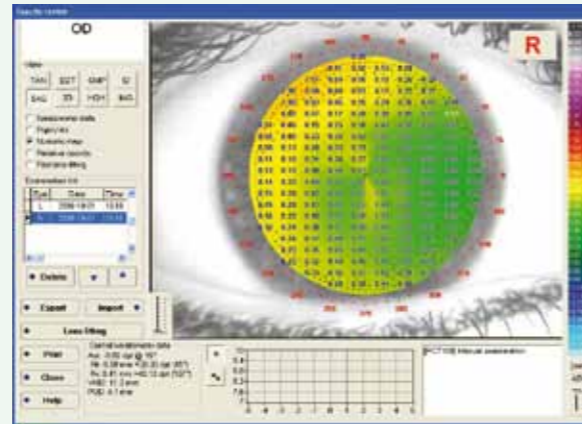
The first lenses ordered and dispensed after first inspection and assessment were:

### Mini Misa Scleral:

OD Vault	3.50/S+0.25/BCR 8.80/Ø 16.50/SC 13.75/LZ Wide
OS Vault	3.25/S+0.50/BCR 8.80/Ø 16.50/SC 13.75/LZ Wide

### 1st follow-up

The patient was very satisfied. Comfort was good and the dry eye symptoms were reduced. Maximum wearing time was 8 hours (two periods of 4 hours). Within the 8 hours, no artificial tears were used. The BCVA was good with OD 1.0 and OS 0.9. Slit lamp examination revealed no blanching, with the cornea and conjunctiva in good health, and no haze was found. We planned see the patient again in six weeks for a regular check up.



## Summary & Discussion

The goal to decrease the dry eye symptoms was met in this patient. She was able to wear lenses again for a longer period of time, and perhaps in the future the wearing time will increase even more. This case demonstrates that scleral lenses can be an excellent indication for cases of dry eye. The tear reservoir can significantly decrease the dry eye symptoms.



indication



keywords

# Keratitis sicca

Edmond A. Smit

Keratitis sicca | lagophthalmus | ptosis

## Introduction

This patient presented with severe keratitis sicca OD because of lagophthalmus that resulted from a cranial nerve VII - facial paresis after a brain tumor and a ptosis OD. We were able to fit her with a full scleral lens (20 mm) to keep the ocular surface moist and to preserve the cornea. Overnight this patient wears a soft bandage lens to protect her cornea.

## Subjective & objective findings

A 36-year-old diabetic patient presented with keratitis sicca and ptosis OD as a result of nerve VII paresis. She was currently wearing a soft lens S -3.50 OS.

### Refraction:

VOD	sc 0.05 (could not be improved)
VOS	cc 1.0

### Keratometry OD:

8.34/8.64 mm, irregular pattern

● **Slit lamp:** examination revealed substantial neovascularization of the cornea and staining of the cornea and conjunctiva OD. OS was unremarkable.

The first lens ordered and dispensed for OD after first inspection and assessment was:

### Misa Scleral:

Vault	3.75/S -8.00/BCR 7.90/Ø 21.5/SC 14.75/LZ normal
(see slit lamp images of the lens with fluorescein (frontal view and with optical section).	
VOD	cc 0.05

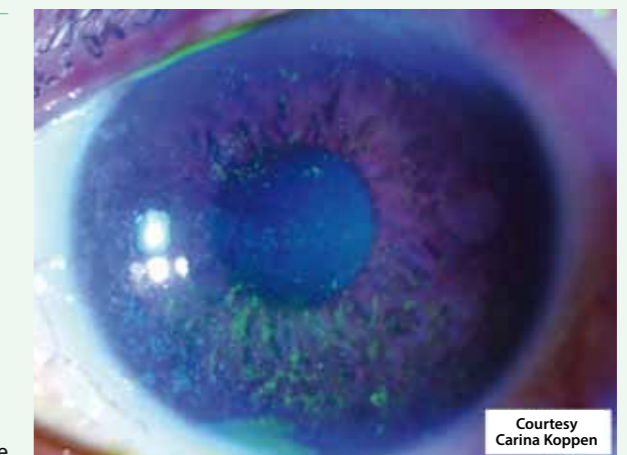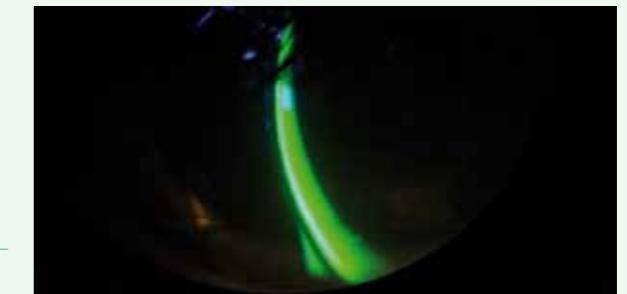
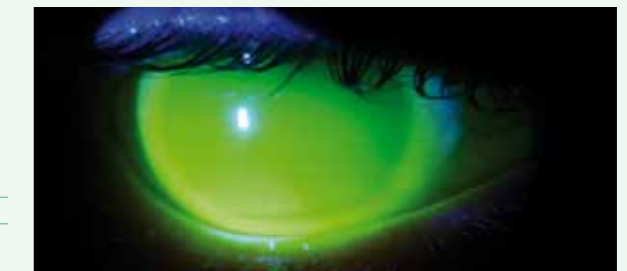### 1st and 2nd follow up visit

The third day after dispensing, upon waking, the patient reported a problem with her right eye and came in for an emergency visit. The cornea exhibited intense epithelial fluorescein staining. Normally she used Duratears (Alcon) ointment overnight, but she had stopped doing that after she started wearing the scleral lens. We provided her with a bandage lens to wear overnight and asked her to wear the scleral lens during the day. At the 2nd follow up visit 2 weeks later, the situation had cleared and the cornea was in much better shape.

### 3rd follow up visit

The patient reported wearing the lens every day, all day long. Every 5 hours she would renew the unpreserved saline solution. During the night she was still using the soft bandage

lens. The scleral lens fit centrally and peripherally was good, with adequate clearance. Because of the vault of the scleral lens, the ptosis was also reduced. The eyelid apertures OD and OS were almost equal. We will see her now for regular six month interval check-ups.



Courtesy Carina Koppen

## Summary & Discussion

This patient has been wearing the scleral lens for years now with success. This case proves the extreme difference scleral lenses can make. Even in severely compromised corneas, scleral lenses can prove beneficial in creating a moist environment to nurture the cornea. In fact, in many of the long-standing and advanced scleral lens practices around the world, corneal protection is one of the main indications for fitting scleral lenses. Scleral lenses are not recommended to be worn on an extended wear basis, hence this patient is still using the soft bandage lens overnight.

Many exposure keratitis/ocular surface disease patients (see slit lamp image of a exposure keratitis eye showing significant corneal staining, courtesy of Carina Koppen) can particularly benefit from scleral lenses because of the retention of a

fluid reservoir behind the scleral lens. Sjögren's syndrome is a common scleral lens indication. Under this category also falls conditions such as persistent epithelial corneal defects, Steven's Johnson Syndrome, Graft Versus Host Disease, ocular cicatricial pemphigoid, neurotrophic corneal disease and atopic keratoconjunctivitis. Also, if lid closure is incomplete such as in eyelid coloboma, exophthalmus, ectropion, nerve palsies and after lid retraction surgery, a scleral lens may be a good indication. In addition, scleral lenses have proven to be effective in protecting the ocular surface in cases of trichiasis and entropion. Scleral lenses have also been reported to show excellent results in acusticus neurinoma.

Source: Van der Worp, E - A Guide to Scleral Lens Fitting 2011 (<http://commons.pacificu.edu/mono/4/>)



Case



Gender: Female

Age: 37



discussion



Case



Gender: Female

Age: 36



discussion



## Scleral Lens Fitting

Learning to fit scleral lenses involves a learning curve, and this chapter discusses some of the challenges that scleral lens fitters can face. One of the first and primary tasks of a scleral lens fitter is to 'bridge over the cornea.' Corneal clearance is probably the single most important advantage that scleral lenses have over corneal lenses, and it seems advised to take advantage of that. Increasing the sagittal height of the lens causes the lens to "lift" away from the eye, increasing the clearance or vault of the lens. For comparison and as a reference when evaluating the clearance on-eye, the average corneal thickness of a normal eye is about 530 microns in the center of the cornea, with values up to 650 microns in the periphery near the limbus, and this can be used as a reference when evaluating corneal clearance on-eye. However, caution should be taken as some of the corneas that we manage no longer have their original corneal thickness (such as in keratoconus, corneal transplants etc). Central lens thickness, if known, can also serve as a reference point.

Scleral lenses may need some time to settle as they can "sink" into the conjunctiva to some degree, which is subject to high individual variance. It is therefore advised at the first scleral lens fit to build in a margin of error – in other words, to overcreate a clearance area. This is especially true in cases with intrastromal rings, as a case report in this chapter will clearly highlight. The practitioner wants to ensure that the lens stays clear of the stromal rings at all times to prevent a potential melting of the cornea and extrusion of the ring segments.

This also emphasizes the need for regular check ups for scleral lens wearers. Keratoconus, for instance, is a progressive disease, and sometimes the scleral lens sagittal height needs to be adjusted as is illustrated by one of the case reports in this chapter. Another case highlights the same issue in a cornea undergoing corneal crosslinking for keratoconus, after which significant corneal changes occurred and a refit was indicated.

Sometimes when a scleral lens is placed on the eye, it presses more on one segment of the conjunctiva, possibly resulting in blanching in one or two segments beneath the lens. Toric or quadrant specific scleral lenses are now available as an alternative to overcome this problem in a more structured and controlled way. The toric or quadrant specific portion of these lenses is located in the landing zone; the optical zone is free of any toricity unless optically a front toric correction is added to the lens. A number of case reports in this chapter will address this issue and look at toric scleral or quadrant specific lens fitting and its benefits.

Regarding residual astigmatism: in theory, if no toric back surface design is used or if for some reason the lens is not stable on the eye, front toric optical correction may be an option to correct residual astigmatism. However, it may be easier and possibly cheaper to simply prescribe a pair of spectacles to be worn over the scleral lenses to correct this as indicated by one of the cases in this series. The same is true for the correction of presbyopia, as a case in this chapter will illustrate: a multifocal pair of glasses proved to be a very satisfactory solution after the patient was fit with scleral lenses.

Also in this chapter is an exceptional case of lens fitting in which some knowledge of optics combined with a critical amount of creativity helped create a low vision aid. With that the patient is able to read the train signs at the station and for the first time she went to a discotheque with friends. This shows that scleral lens specialists can really make a difference in some patients' lives.

Finally, to complete this overview, a very special case in this series is of a hand-painted scleral lens for aesthetic reasons in a 34-year-old woman with a shrunken eye. Fitting hand-painted contact lenses can be both very challenging and extremely rewarding, as this case illustrates.

# 2





indication



keywords

11

Case



Gender: Male

Age: 27

# Penetrating keratoplasty, corneal clearance & conjunctival 'sinking'

Jaap van Blitterswijk, Cristian Mertz, Marjolijn Bartels

Penetrating Keratoplasty (PKP) | corneal clearance | sagittal depth | conjunctival 'sinking'

## Introduction

This case report is about a patient who underwent a PKP ODS 15 years ago. He had never worn contact lenses since, but his glasses provided suboptimal vision. He was referred by the ophthalmologist to explore the possibilities for sclera lens wear with respect to tolerance and gain in visual acuity. This case report also discusses the importance of sufficient corneal clearance at dispensing, as scleral lenses tend to 'sink' into the conjunctiva.

## Subjective & objective findings

A 27-year-old male was diagnosed with keratoconus and underwent a bilateral PKP 15 years ago. His visual acuity was suboptimal. His general health was unremarkable.

### Refraction:

VOD	S- 4.00 C -1.50 @ 66	VA 0.5
	with pinhole glasses:	VA 0.8
VOS	S- 2.50 C-7.00 @ 20	VA 0.7
	with pinhole glasses:	VA 0.8

● **Corneal topography:** see Oculus Pentacam images Figures OD and OS.

● **Slit lamp:** OD=OS status after PKP. Clear corneal transplant. Grade 1 cortical cataract ODS. See Oculus Pentacam Scheimpflug images OD and OS, respectively.

Given the suboptimal best-corrected visual acuity, the improvement in vision with pinhole glasses, the corneal topography and the measured refractive correction (especially the high cylinder OS), scleral lenses were considered for this patient for optimal vision.

First trial lens:

**Mini Misa Scleral T:**  
OD Vault 3.75/S-2.50/BCR8.40/Ø16.5/SC13.5-13.0/LZ normal  
OS Vault 3.25/S-4.50/BCR7.80/Ø16.5/SC13.0-13.0/LZ normal

These lenses were ordered, and at dispensing a first inspection and assessment of the lenses was made. After 90 minutes of wearing time, the right lens demonstrated central touch on the cornea. Because of this, the sagittal height of the lens had to be increased to 4.00 (an increase of 250 microns). Therefore, a new lens was ordered for the right eye:

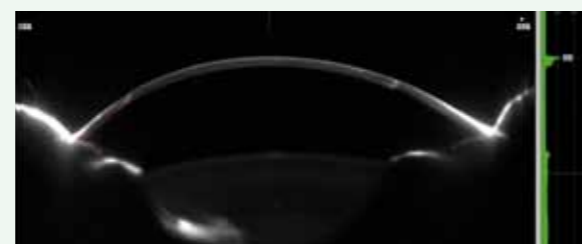
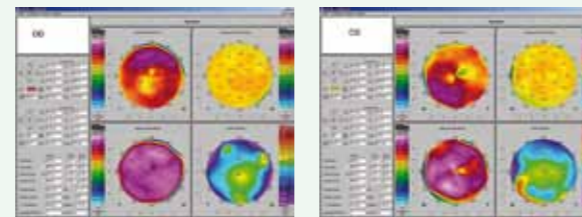
**Misa Mini Scleral T:**  
OD Vault 4.00/S-2.50/BCR8.40/Ø16.5/SC13.5-13.0/LZ normal

## 1st follow up visit

After six weeks the patient was seen for his follow up examination. Subjective vision was reported to have improved substantially. The lenses could be worn all day. Every 4-5 hours, the lenses were removed, cleaned and reapplied with fresh solution.

VOD	cc 0.8
VOS	cc 0.6

The vision OS was slightly less than it was for OD, but no apparent reason for this could be determined. The power of the lens was checked and found to be optimal, and the lens fit was optimal. Vision could not be improved with over-refraction. We will keep monitoring his vision to see whether it improves or can be improved going forward. We asked the patient to return for follow up in 6 months. An intermediate medical consult with the ophthalmologist was already planned at 3 months.



## Summary & Discussion

This case highlights the importance of eye care practitioners knowing, in a broad sense, about the possibilities that scleral lenses can offer. This PKP patient after keratoconus had been wearing glasses for 15 years before being fit with a scleral lens that improved his subjective vision substantially.

but it can be quite substantial on average and can require a lens change later on. This can be prevented by initially fitting the lens with a substantial surplus of clearance.

One of the key fitting pearl in this case is the fact that scleral lenses tend to 'sink' into the conjunctiva after a while during lens wear. In some cases this is more evident than in others,



discussion



indication



keywords

12

Case



Gender: Male

Age: 27

# Keratoconus, stromal rings & the importance of sufficient corneal clearance

Jan Pauwels, Carina Koppen and Inge Leysen

Keratoconus | stromal rings | corneal clearance | lens 'sinking'

## Introduction

This case report describes a patient with keratoconus ODS. Several attempts were undertaken to fit the patient with a special soft keratoconus lens design, as he was RGP-lens intolerant. Despite the efforts, the visual acuity OS could not be improved beyond 0.3 because of the severe corneal irregularities. Also, large diameter scleral lenses were tried in the initial phase, but because this resulted in poor wearing comfort the patient decided to undergo a stromal ring implant ODS. Unfortunately, the visual outcome of this was not optimal. The best-corrected visual acuity OD with the stromal ring implants was slightly worse than the acuity with the soft lens, reaching a VA of 0.8. A slight improvement OS was noted, up to a VA of 0.5. Not long after the stromal ring implant, the patient was referred back to our contact lens practice for a refit with the newly available MISA scleral lenses in a final attempt to optimize vision.

## Subjective & objective findings

This scleral lens fit concerns a 27-year-old male keratoconus patient after corneal ring implants ODS. The central cornea remains clear ODS.

### Refraction:

VOD with own correction	S -5.00 C -2.25 @ 50	VA 0.7
VOS with own correction	S -7.00 C -2.50 @ 170	VA 0.2

● **Corneal topography:** irregular cornea ODS

● **Slit lamp:** see Oculus Pentacam images OD and OS, before (top) and after ring segment implantation (bottom).

The first lens ordered and dispensed after first inspection and assessment was:

**Mini Misa Scleral:**  
OD Vault 3.75/S-0.00/BCR 7.80/Ø 16.50/SC 13.5/LZ normal  
OS Vault 3.75/S-0.00/BCR 7.80/Ø 16.50/SC 13.5/LZ normal

### Over-refraction:

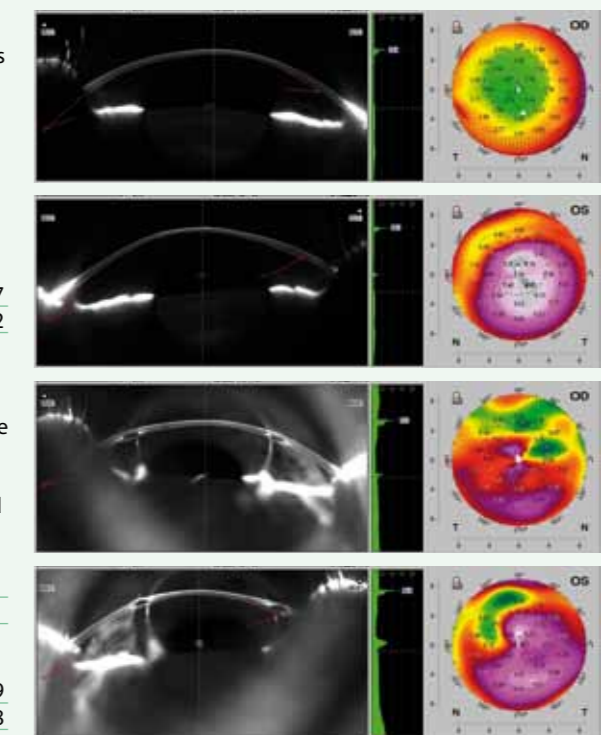
VOD	cc 0.8	over-refraction	S -0.75	VA 0.9
VOS	cc 0.6	over-refraction	S -0.75	VA 0.8

Because the patient does mainly computer work, he uses a pair of glasses when driving his car, while keeping his scleral lenses prescription at the current parameters.

## 1st follow up visit

At the first follow up visit at four weeks, the patient was satisfied with the VA OU. On slit lamp evaluation it was noted that the clearance was minimal, and in fact the back surface of the lens was touching the upper ring segment OD. A lens with a higher vault was ordered (Misa vault 400) to overcome this problem:

**Mini Misa Scleral:**  
Vault 4.00/S-0.00/BCR 7.80/Ø 16.50/SC 13.5/LZ normal



© Photographs: University Hospital Antwerp (Belgium).

## Summary & Discussion

Scleral lenses have the tendency to 'sink' into the conjunctiva and possibly into the underlying Tenon's capsule – which both consist of soft tissue. Studies at Pacific University (Patrick Caroline, Randy Kojima, personal communication 2012) have revealed that scleral lenses sink between 50 and 200 microns on normal adolescent eyes after eight hours of lens wear (30 eyes of 15 patients with two different lens designs) – hence there is great variability. Typically, in elderly patients both the conjunctiva and Tenon's capsule become thinner. Theoretically this could mean a lesser degree of 'sinking.' In either case, it is always advised at the initial scleral lens fit to build in a margin of error – in other words, to overestimate the clearance area. This is especially true in cases like this with intrastromal rings. In scleral lens fitting, you want to make

sure that the lens stays clear of the stromal rings at all times to prevent a potential melting of the cornea and extrusion of the ring segments.

Letting the lens sit for a longer period of time during the fitting process can help in better assessing the lens fit and its clearance, and possibly can help prevent having to reorder lenses with a higher vault to avoid touching the top of the cone or ring segment as in this case. The outcome of stromal ring implants, although beneficial in some patients, can be very unpredictable. Fitting standard soft or RGP lenses post-stromal ring implant is very challenging. Scleral lenses remain the only viable option oftentimes, with potentially substantial visual acuity gain.



discussion

# Progressive corneal ectasia

Chrétien Frambach

Keratoglobus | keratoconus | progressive myopia

13  
Case



Gender: Male

Age: 43



discussion

## Introduction

A 43-year-old male patient complained of progressive myopia and a decrease in vision. His contact lens specialist advised him to wear soft lenses, but when his vision gradually decreased he was advised to visit an ophthalmologist. Measurements with the Oculus Pentacam revealed a thin cornea and protrusion ODS.

## Subjective & objective findings

A 43-year-old male presented with progressive myopia and a decrease in vision.

### Refraction:

VOD	S -15.50 C -2.25 @ 61	VA 0.05
	with pinhole glasses:	VA 0.3
VOS	S -14.00 C -3.50 @ 168	VA 0.55
	no improvement with pinhole glasses	

History of refraction revealed a spherical refraction of S -2.00 at 14 years of age. His best vision ever reported was 0.8 at 17 years of age.

- **Corneal topography:** see Oculus Pentacam elevation maps OD and OS with evident ectasia visible.
- **Slit lamp:** examination revealed clear corneas without any signs of Fleischer's ring, striae or scarring. However, the protrusion ODS was evident and significant (see slit lamp image). The diagnosis was possibly keratoglobus based on the slit lamp findings and description of symptoms (a slow progressing myopia with reasonable vision up to the age of 43), although the differential diagnosis from keratoconus (which, based on the topography images, is another likely diagnosis) was not easy. Because of the ectasia of both corneas, scleral lenses were fitted. The initial comfort was very good. Vision ODS increased instantly to 1.0 OU.

The initial diagnostic lens with a vault of 350 OD provided good fitting characteristics, good limbal clearance and total

clearance of the cornea. On the inferior side of the haptical zone, the lens did not land on the sclera. See scleral lens fit images with fluorescein (frontal view and optical section). Increasing the vault height to 375 resulted in a better landing of the haptical zone.

For OS the initial diagnostic lens with a vault of 325 exhibited suboptimal fitting characteristics. Limbal clearance and corneal clearance were still good, but the haptical zone lifted off a little more compared to the right lens. The lens OS was also bearing on the cornea inferiorly. It was decided to increase the vault in both eyes. This would prevent the lens periphery from partially landing on the protrusion. If the increased vault is not satisfactory going forward, a larger overall lens diameter may be considered as an alternative approach.

### Mini scleral lenses were ordered and dispensed:

OD Vault	3.75/S-4.75/BCR 7.80/Ø 16.5/SC 13.5/LZ normal
OS Vault	3.75/S-5.75/BCR 7.80/Ø 16.5/SC 13.5/LZ normal

### 1st follow up

At the first visit after one week of lens wear, the patient was very pleased. His vision was 1.0 ODS. Both corneas were clear and without any epithelial defect. Cleaning with an abrasive cleaner was advised to maintain a smooth surface. The lenses were easy to handle. A larger lens was not considered at this point as the patient was satisfied and the cornea looked good.

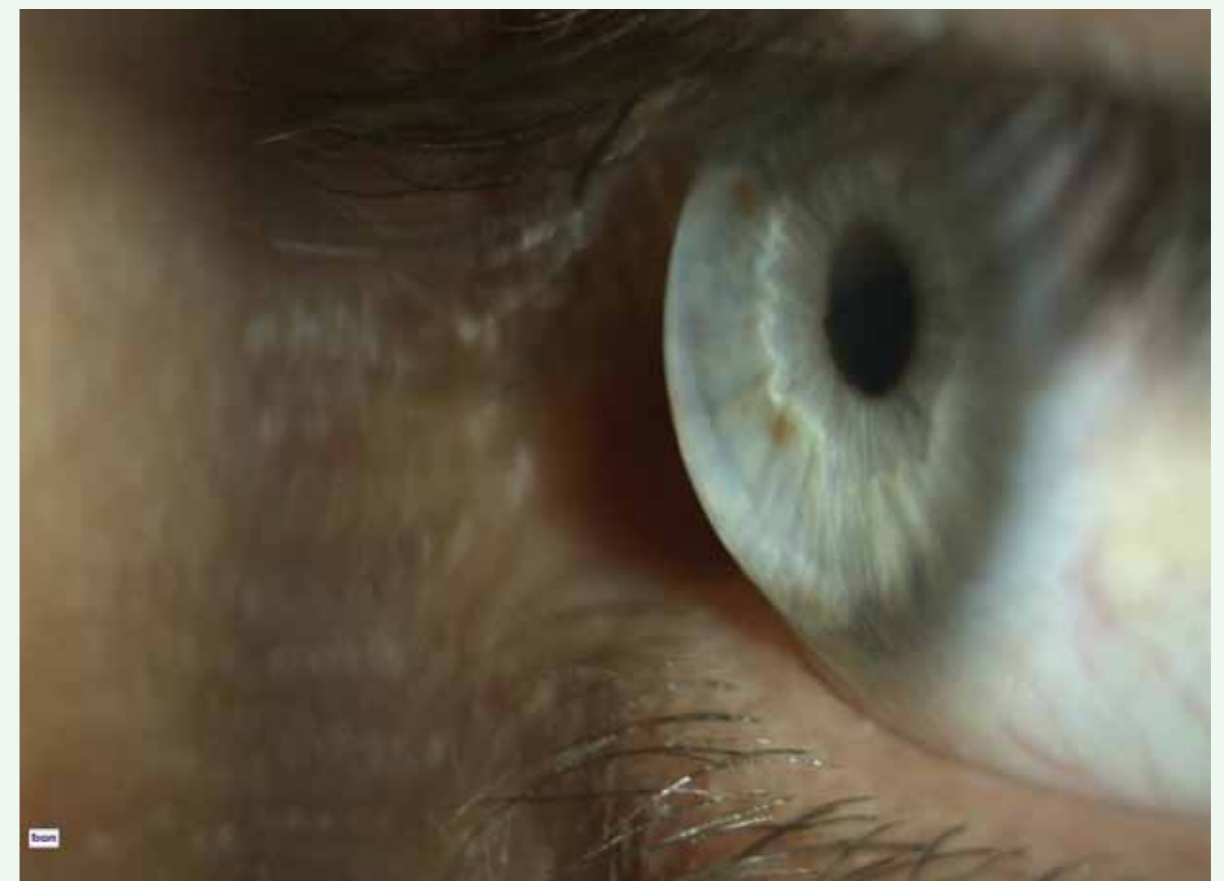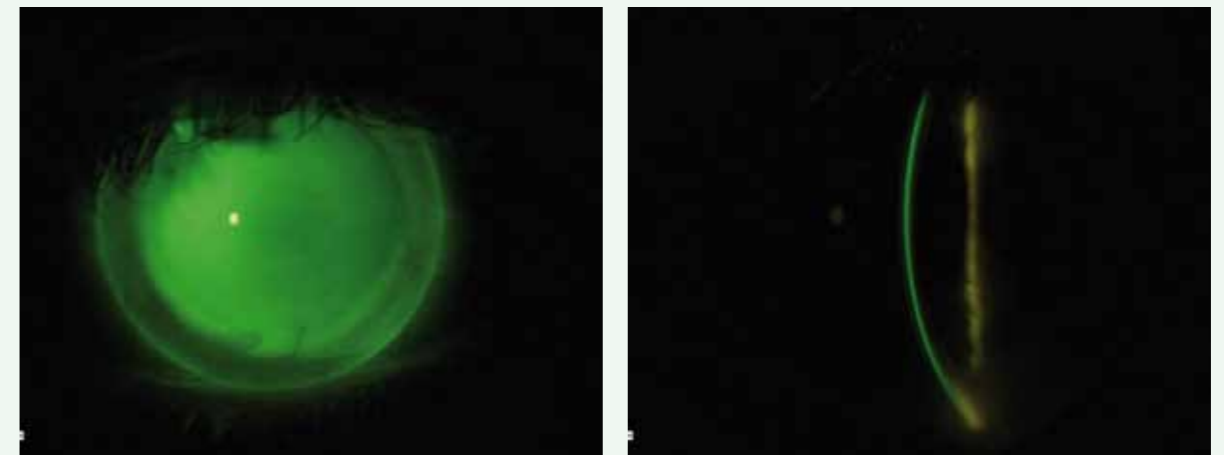
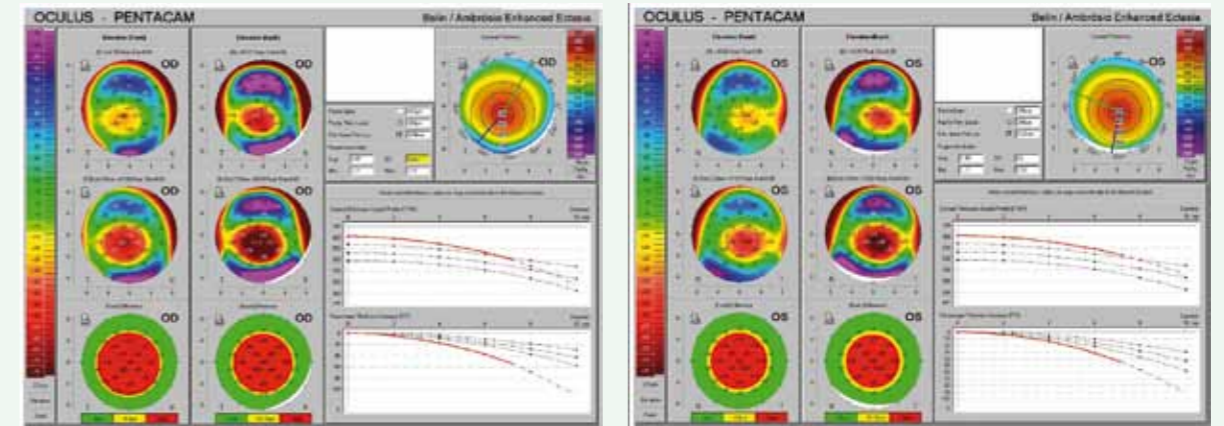
## Summary & Discussion

A few 'take home messages' can be distilled from this case report. Before anything else: sometimes, as in this case, it is difficult to make the differential diagnosis of keratoglobus versus keratoconus (as discussed under the slit lamp findings in this case report). But this does not make a difference when fitting scleral lenses. Bridging over the protrusion will be the best optical solution, regardless of the exact underlying cause of the ectasia.

Even progression of ectasia under a scleral lens is relatively without consequences, as the tear clearance will mask most corneal irregularities. In some cases, this saves the patient from purchasing multiple lenses in cases of progressive refractive states. The only point of interest is to make sure the protrusion does not touch the back surface of the lens at any given moment in time. Regular check ups for scleral lens wearers are strongly advised.

A separate topic regarding this case report is the total diameter of the scleral lens. Some practitioners advocate full scleral lenses (typical diameter range 18-24mm), while others are convinced that corneo-scleral lenses (typical

diameter range 12.5 - 15.0 mm) are desired in many cases. The main difference between these is the tear reservoir that can be created. Typically, the larger the scleral lens diameter, the larger the tear reservoir capacity. Large tear clearances are also sometimes desired with extreme protrusions or in ocular surface disease. With bigger lenses, a much larger area of bearing is created in the landing zone area, which prevents local areas of excessive pressure and may improve comfort. Small diameter lenses typically "sink" more into the conjunctiva and may exhibit less movement than large diameter scleral lenses. In favor of smaller scleral lenses is the fact that with smaller diameter lenses you can avoid having to fit severe scleral irregularities as described in other case reports in this series. Also, smaller tear reservoirs may lead to a better oxygen delivery to the cornea. A point that is less often made is the handling comfort of the lenses for the patient. Corneo-scleral lenses may be easier to handle than full scleral lenses, which can be a consideration in scleral lens fitting. It should be noted that success with scleral lens fitting depends on more than just a perfect technical lens fit. Patient considerations, such as ease of lens handling, are of critical importance as well.





indication



keywords

14

Case



Gender: Male

Age: 27

# Scleral lens fitting and corneal crosslinking

Cristian Mertz, Jaap van Blitterswijk, Marjolijn Bartels

Corneal crosslinking (CXL) | keratoconus | corneal changes | refit

## Introduction

A young male patient discovered that his acuity was suboptimal when he started driving lessons, and he was referred to us. There were no subjective complaints. The ophthalmologist diagnosed the patient with a bilateral keratoconus. If progression could be observed, crosslinking should be considered. In the meantime the ophthalmologist requested a consult for scleral lens fitting.

## Subjective & objective findings

A 27-year-old male was diagnosed with bilateral keratoconus. He had no real vision complaints. The patient was healthy, used no medication and had no allergies.

● **Refraction:**

VOD	S -2.25 C -2.75 @ 34	VA 0.6
	pinhole	VA 0.7
VOS	-4.75 C -5.75 @ 148	VA 0.2
	pinhole	VA 0.5

● **Corneal topography:** see Microlens topographer images OD and OS before (top) and after (bottom) CXL.

● **Slit lamp:** healthy cornea OD, OS thinning of the central cornea is visible.

The first lenses ordered and dispensed after first inspection and assessment were:

**Misa Full Scleral:**

OD Vault	325/S +1.00/BCR 7.80/Ø 20.0/SC 13.5/LZ Normal
OS Vault	325/S +1.00/BCR 7.80/Ø 20.0/SC 13.5/LZ Normal

## 1st follow up visit

The first two weeks of wear were rather successful. The acuity had significantly improved and the comfort was sufficient for the whole wearing period. Application of the lens was improving, although the right lens still gave some difficulty. The lenses were worn the whole day without refreshment of the solution. The right eye had been suffering from irritation and redness after lens removal.

● **Over-refraction:**

OD	S 0.00	VA 0.8
OS	S 0.00 C -1.00 @ 60	VA 0.6

The lens fit appeared optimal, although there was a small bubble present peripherally. After reapplication with fresh solution, the bubble was once again visible. We advised him to refresh the solution every 4-5 hours and to continue practicing application and removal, as improving the technique may reduce bubble occurrence.

## 2nd follow up

Two weeks after the last visit, there were no more complaints with the right or left eye. Application had definitely improved. The fit and acuity were stable. Revision was scheduled for 3 months.

## Cross-linking

After a check-up by the ophthalmologist, progression of the corneal thinning was observed for both eyes. OS was now at the threshold of 400um thickness for undergoing cross-linking treatment. The patient was scheduled to return for a checkup 3 months after the left eye cross-linking treatment had taken place; in the meantime, no contact lenses could be worn.

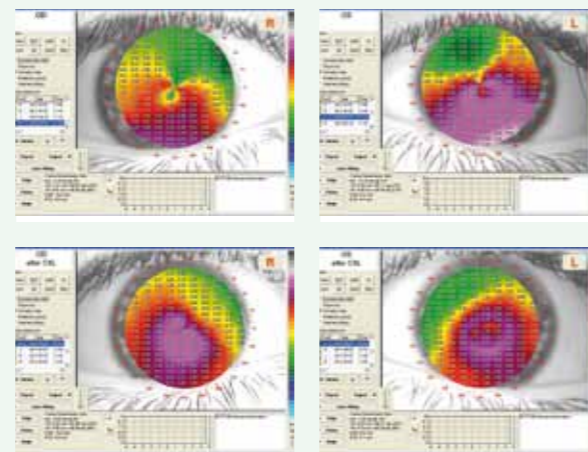
## Follow up after cross-linking left eye

The treatment was carried out successfully; the keratometry-values OS were unchanged (see topography images OD and OS after CXL). But after the lens was applied it was clear that the fit was no longer optimal: central touch and peripheral bubbles were visible OS. The lens vault needed to be raised to 350. Other parameters remained unchanged.

Final lens:

**Misa Scleral:**

OD Vault	325/S +1.00/BCR 7.80/Ø 20.0/SC 13.5/LZ Normal
OS Vault	350/S +1.00/BCR 7.80/Ø 20.0/SC 13.5/LZ Normal



## Summary & Discussion

As we have seen with other cases in which the patient was treated with cross-linking, the parameters of the cornea appeared to be unchanged based on central keratometry values. But despite this, the lens fit had changed and the parameters had to be re-adjusted – possibly the overall

sagittal height of the eye had been altered. Our advice now is to always check the fit of the lens after cross-linking, before the patient starts wearing the lens full time.



discussion

# Toric scleral lens in a keratoconus patient

Jan Pauwels, Bernard Duchesne and Jean Claude Delcourt

Keratoconus | conjunctival blanching | toric scleral lens

## Introduction

A young keratoconus patient with suboptimal visual acuity OS was fitted with a scleral lens for that eye. The visual acuity improved to 1.0 OS, but from the very first time the patient applied the lens she reported discomfort, specifically in the lower eyelid region. Slit lamp findings revealed a classic toric scleral shape, with conjunctival blanching in the horizontal meridian and edge stand-off in the vertical meridian. A toric MISA lens was then considered as an option.

## Subjective & objective findings

The 23-year-old female patient with keratoconus reported poor vision in her left eye:

● **Refraction:**

VOD	sc	VA 1.2
VOS	S -2.00 C -2.75 140	VA 0.4
		Pinhole: 0.7

● **Corneal topography:** irregular cornea OS (see Oculus Pentacam images OD and OS).

● **Slit lamp:** clear corneas. Vogt's striae visible OS.

The first lens ordered and dispensed after first inspection and assessment was:

**Mini Misa Scleral:**

OS Vault	3.75/S+1.25/BCR 7.80/Ø 16.50/SC 13.5/LZ normal
----------	--

● **Over-refraction:**

	S +1.00 C -1.50 @ 50	VA 1.0
--	----------------------	--------

## 1st follow up visit

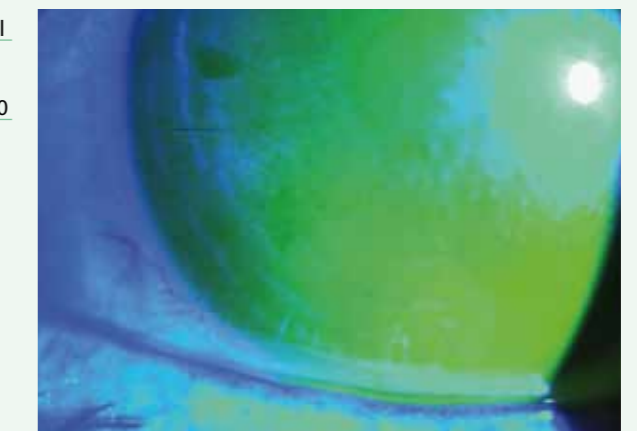
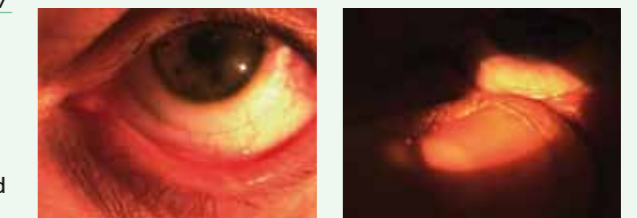
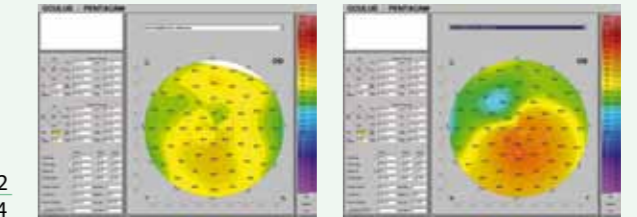
Ever since the dispensing visit, the patient had reported inferior lens edge discomfort. This continued and even worsened with longer wearing hours during the adaptation phase – up to the point that she was almost unable to wear the lens anymore. Slit lamp examination after 6 hours of lens wear revealed significant conjunctival blanching nasally and temporally, while a lift-off was seen inferiorly (see slit lamp images). A Mini Misa Toric 1 lens was ordered for this patient with a scleral toricity of 0.75mm. The other lens parameters remained the same:

## Mini Misa Toric Scleral T1:

OS Vault	3.75/S+1.25/BCR 7.80/Ø 16.50/SC 13.5/LZ normal
----------	--

## 2nd follow up visit

With the toric Mini Misa scleral lens (see slit lamp fluorescein image), comfort was good and a wearing time of at least 12 hours per day was achieved.



© Photographs: University Hospital Liège (Belgium).

## Summary & Discussion

This seemed a pretty straightforward scleral lens fit, with suboptimal vision in one eye. The evaluation of the first trial lenses took place fairly soon after lens placement. Sometimes it is better to leave the lens on for a significant period of time, preferably for a few hours, before evaluating the lens. The toric nature of the sclera in this case would most probably have been revealed then and a toric scleral lens could have been fitted immediately, preventing the patient from having an initially negative scleral lens experience.

Recent research shows that in general, the limbus and anterior sclera of the average eye is non-rotationally symmetric in nature, meaning that some parts of the ocular surface beyond the cornea are flatter or steeper than others. If the lens diameter is smaller than 15 mm, it's been found that

these differences are limited – on average about 100 microns of difference may be present. However, great individual variation exists. In some subjects, more than 600 microns of difference within one eye have been found. And beyond 15 mm diameter, the differences certainly become more marked. In the 15-20 mm ring, a mean of 400 microns of difference have been found within the average eye – but in individual eyes up to 1,000 microns of difference have been found. This seems highly clinically significant, calling for more quadrant specific and toric scleral lens fits. As said – this is especially true for the larger diameter scleral lenses.

Source: Van der Worp, E – Pacific Scleral Shape Study results, presented at the Global Specialty Lens Symposium, Las Vegas (USA) January 28th 2012



indication



keywords

15

Case



Gender: Male

Age: 40



discussion



indication



keywords

16

Case



Gender: Male

Age: 43

# Herpes Keratitis & quadrant specific scleral lenses

Cristian Mertz, Jaap van Blitterswijk, Marjolijn Bartels

Herpes Keratitis | palpebral fissure | corneal transplant | non-rotationally symmetric lenses

## Introduction

This case reports on a bilateral Herpes Keratitis. The patient reported having had an infection at the age of 3. His VA was variable; he wore spectacles but the VA was poor with them because of the irregular cornea and stromal scarring. The ophthalmologist was considering a Deep Anterior Lamellar Keratoplasty (DALK), but first wanted to try the option of scleral lenses.

## Subjective & objective findings

A 43-year-old man was diagnosed with Herpes Keratitis ODS. He had poor VA with spectacle wear. The patient was healthy, used no medications and had no allergies.

### Refraction:

OD	S +3.75 C -2.75 @ 5 pinhole	VA 0.5 VA 0.6
OS	S +1.50 C -1.00 @ 180 pinhole	VA 0.5 VA 0.6

● **Corneal topography:** see Microlens topographer images OD and OS (with keratometric overlay in mm).

● **Slit lamp:** examination revealed corneal scarring ODS, OS ghost vessels superiorly all the way to the centre of the cornea.

Given the irregular cornea, we advised fitting scleral lenses for both eyes.

The lenses ordered were:

**Misa Full Scleral:**

OD	Vault 300/S -2.75/BCR 7.80/Ø 21.5/SC 13.75/LZ normal
OS	Vault 325/S -3.25/BCR 7.80/Ø 21.5/SC 13.75/LZ normal

During first inspection it was clear that the diameter of the lenses had to be increased in both eyes. The patient had a large palpebral fissure (12 mm ODS). The lens edge was catching on the inferior eyelid and making it very uncomfortable to wear the lenses. We ordered new lenses with a diameter of 23.0 mm while keeping the rest of the parameters the same. At the next inspection, the fitting of the left eye was good. In the right eye there was a significant edge clearance inferiorly, so we switched to a non-rotationally symmetric T1 scleral lens. These lenses were dispensed.

## 1st follow up visit

The vision had increased compared to the spectacles. The wearing time was 10 hours maximum, after which the comfort would decrease. The patient would remove and reapply the lenses after five hours. He had problems with removing the left lens, and after removal he often presented with a slightly red eye.

### Over-refraction:

OD	S 0.00	VA 0.7
OS	S 0.00	VA 0.7

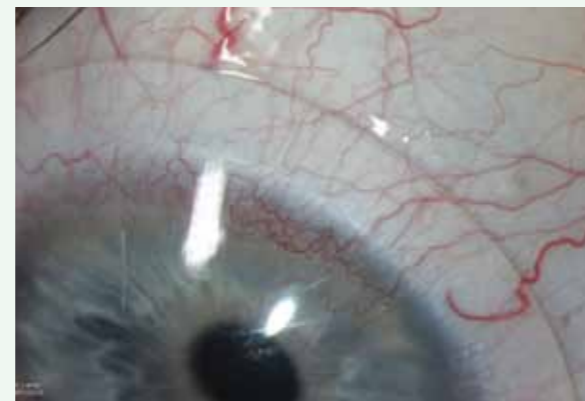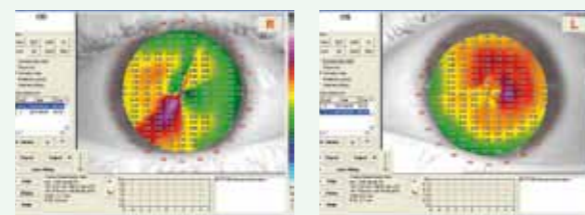
The lens fitting of right eye was good. In the left eye we could see some blanching inferior temporal. A lens with a flatter scleral curve was ordered:

**Misa Full Scleral T1:**

OS	Vault 325/S -3.25/BCR 7.80/Ø 23.0/SC 14.25/LZ toric
----	---

## 2nd follow up visit

After 6 weeks we saw the patient again. He could wear the lenses all day and reapply the lenses after a maximum of six hours. He was pleased with the result. In consultation with the ophthalmologist, it was decided not to undergo transplantation as long as the scleral lenses provided acceptable results.



## Summary & Discussion

This case report demonstrates that as long as a solution with contact lenses is possible, this is preferred over undergoing a risky and costly penetrating keratoplasty. This procedure can be postponed or even prevented by using scleral lenses. Also, the life of corneal transplants is limited and therefore is not a preferred option in younger patients. This case also shows us the use and/or need in some cases of a non-rotationally

symmetric scleral curve. If you want to decrease blanching in one quadrant or decrease the leaking of fluid from behind the lens, one quadrant can be flattened or steepened with these lenses – which can be a powerful tool. See slit lamp image (courtesy of Jan Pauwels) of a toric scleral lens with a mark (vertical line) on the lens indicating the flattest meridian.



discussion



indication



keywords

17

Case



Gender: Male

Age: 41

# Keratoconus & the potential need for supplemental glasses

Jaap van Blitterswijk, Cristian Mertz, Marjolijn Bartels

Keratoconus | rest correction | front cylinder | glasses

## Introduction

This case report describes a successful mini scleral lens fit in a patient diagnosed with keratoconus who had never worn lenses before. With the combination of his pair of mini scleral lenses and a pair of supplemental glasses, he could return to his work as a professional bus driver.

## Subjective & objective findings

A 41-year-old man wore glasses, however his best corrected visual acuity with glasses was low. He first noted the shift in vision about 6 months ago. The ophthalmologist's examination revealed keratoconus ODS. Normally, one of the options in such cases may be intracorneal ring segments. However, this was considered a suboptimal treatment for this patient because he was a professional bus driver, and he may experience glare and flare with this procedure. The referring ophthalmologist wanted to know whether contact lenses could improve his vision sufficiently to return to his job safely. The patient was currently wearing glasses, and no contact lenses had been tried before. His general health was unremarkable.

### Refraction:

VOD	S -2.50 C -3.00 @ 86 with pinhole glasses	VA 0.16 0.7
VOS	S -2.75 C -2.50 @ 94 with pinhole glasses	VA 0.2 0.7

● **Corneal topography:** see Oculus Pentacam images OD and OS.

● **Slit lamp:** Examination revealed keratoconus OS > OD. His corneas revealed no staining. Tear meniscus height and tear break up time were unremarkable. Corneal thinning was visible in the Scheimpflug image (Oculus Pentacam).

The plan was to fit mini scleral lenses because of the severity of this patient's corneal irregularity, with the goal to substantially improve vision.

The first lenses ordered and dispensed after first inspection and assessment were:

**Misa Mini Scleral:**

OD	Vault 3.25/S -7.00/BCR 7.40/Ø 16.5/SC 13.5/LZ wide
OS	Vault 3.25/S -5.50/BCR 7.40/Ø 16.5/SC 13.5/LZ wide

### Over-refraction:

VOD	cc 0.7	S 0.00 C -2.00 @ 130	VA 1.0
VOS	cc 0.65	S 0.00 C -1.50 @ 50	VA 0.8

## 1st follow up visit

This first check up after 1 week revealed that the lens wearing comfort was reasonable. The maximum wearing time was limited to about 5 hours. He was still having some problems with lens handling (placement & removal). Visual acuity OD seemed to be somewhat better than OS subjectively.

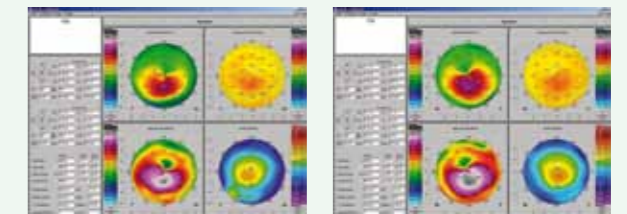
### Over-refraction:

VOD	cc 0.6	S -1.50 C -1.00 @ 130	VA 1.0
VOS	cc 0.65	S 0.00 C -1.50 @ 55	VA 0.8

Lens fit was good, but the prescription was suboptimal. Based on this, the power of the right lens was changed to S -8.50. A prescription for glasses to correct the additional cylinder was provided to optimize his vision. Normally we wait for at least six weeks before we do a final refraction for additional correction, but as this patient relies on his vision occupationally, we provided him with his prescription at this point.

## 2nd follow up visit

The patient was wearing his scleral lenses all day without significant problems. Visual acuity was good, if combined with his supplemental cylindrical correction. A regular 6-month appointment was made.



## Summary & Discussion

This case report shows that for the lens fit to be successful, additional correction may sometimes be needed. This could involve a near add for reading, for instance, or a supplemental cylindrical correction as in this case. In corneal contact lens wear, the additional cylindrical correction can be added to the front surface of the lens. However, dynamic stabilization of scleral lenses has proven to be hard to come by.

front cylindrical correction was not feasible. Also, the quality of the front cylinder on the scleral lens would most likely not be as optimal as with the cylindrical correction in a pair of glasses because of stability and alignment of the cylinder. Hence, the current chosen option was the most simple and effective way of optimizing vision for this patient, who could now return to his original work as a professional bus driver.

Back cylindrical scleral lenses are available with an added front cylinder (hence, a bitoric scleral lens). In these cases, the back toric lens design serves to optimize the lens fit as well as provide stabilization for the cylindrical over-refraction. In this case, no back toric lens design was needed, and therefore a



discussion





indication



keywords

18  
Case

Gender:  
Male

Age:  
55



discussion

# Perforating corneal trauma & presbyopia

Jaap van Blitterswijk, Cristian Mertz, Marjolijn Bartels

Perforating corneal trauma | corneal scar | presbyopia | multifocal glasses

## Introduction

This case reports describes a patient with a poor visual acuity OS after a perforating corneal trauma in early childhood. In this case, a mini scleral lens was fitted for his left eye, under-corrected to be in line with the prescription for his right eye to prevent anisometropia so that multifocal glasses could be worn over his scleral lens OS.

## Subjective & objective findings

A 55-year-old man had a perforating trauma OS more than 50 years ago. Details of the condition are no longer available. He had never worn contact lenses, but was not hesitant to try. His general health was unremarkable. Given his age, a near add correction was required in addition to the distance correction needs.

● Refraction:			
VOD	S +1.75 C -0.25 @ 52		VA 1.0
VOS	sc 0.1 with pinhole glasses		VA 0.3
	Near add +2.25		

● **Corneal topography:** see Microlens topographer image OS (with keratometric values overlay in mm).

● **Slit lamp:** Examination revealed a clear cornea OD, but OS exhibited a superior temporal corneal scar and pupil coloboma superiorly.

Because of his history of the perforating trauma OS, a mini scleral lens was considered to improve visual performance. We started out with a mini scleral design because the patient had never worn contact lenses before, and for such patients a smaller lens may be an easier first step. We started with a wide LZ because of the corneal diameter.

The patient desired multifocal glasses over the scleral lens for his reading demands. Therefore, we decided to create a S+2.00 correction OS, similar to his refraction OD to prevent anisometropia.

The first lens ordered and dispensed after first inspection and assessment was:

**Mini Misa Scleral:**  
Vault 3.25/S-2.00/BCR 8.30/Ø 16.50/SC 13.5/LZ Wide

● Over-refraction:			
VOS	S +2.00		VA 0.7

The desired refractive state was achieved. At this time, no prescription for glasses was provided because we wanted to wait until the scleral lens had settled and the refractive state became more stable.

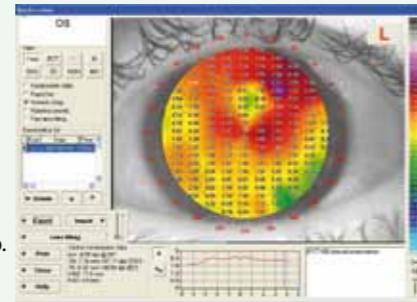
## 1st follow up visit

Two weeks after dispensing, the patient was not entirely satisfied. Visual acuity was not good, and the maximum wearing time of the lens was 4 hours. Our advice was to take more time and to continue following the adaptation program. Over-refraction was VOS S +2.00 VA 0.6. Because of the suboptimal visual acuity, it was decided not to wait any longer and to provide a multifocal prescription of S +2.00 ODS with a near add of S +2.25.

## 2nd follow up visit

Four weeks after the last visit, we saw our patient. Visual acuity, with multifocal glasses, was reported to be good for distance. Over-refraction was VOS S +2.00 VA 0.6. Near vision was still suboptimal. Wearing time was extended to all day at this point, although he was taking the lenses out once to clean and refresh the solution.

Visual acuity for near with trial lenses seemed fine, while with his glasses it was not. We checked his multifocal glasses, and it appeared that his near add was under-corrected from the prescription we had given him. He needed to check this with his optician. His refraction was stable, and the prescription now at 6 weeks after the initial lens fit could be confirmed. We advised the patient to make an appointment for 3 months from now for a regular check up.



## Summary & Discussion

Several interesting points can be distilled from this case apart from the obvious increase in distance visual acuity OS using a scleral lens after long-standing perforating corneal trauma 50 years ago (visual acuity improved from 0.1 to 0.6 in his left eye).

First, in presbyopic patients the need for reading correction is always an extra consideration, including in scleral lens wearers as this case illustrates. More recently, some bifocal scleral lens designs have entered the market. The design of these lenses would fall into the "simultaneous vision bifocal lens design" group, in which two images with different focal points are presented at the same time to the eye. These are most likely more suitable for patients with non-pathological eyes, but combinations should not be excluded in advance. In this case, with the patient wearing a lens only for the left

eye, that solution was not a viable one. Therefore, under-correcting the prescription to match his right eye correction to prevent anisometropia, with an appropriate near add for reading, seemed to be the most optimal, and in this case the most satisfactory, result.

Secondly, it is important for specialty lens eye care practitioners to not automatically blame the scleral lens for unsatisfactory results. In this case, the multifocal glasses were dispensed with an incorrect near add. Occasionally, such external factors can lead to reorders of scleral lenses and multiple follow up visits, which can sometimes be overcome by using common sense. Lastly, this case shows that it often takes time for scleral lenses to settle on the eye, and typically we advise that the lens be used for at least 6 weeks before the final prescription is provided.


# Scleral lenses & low vision

Edmond A. Smit

Low vision | impact of scleral lenses on social behavior



indication



keywords

19  
Case

Gender:  
Female

Age:  
22



discussion

## Introduction

A patient with congenital bilateral optic nerve coloboma and low vision presented to us. Because of her poor visual acuities, she could not participate in everyday activities, function properly in our society and she was challenged in her social environment. An attempt was made, by using a scleral lens in combination with spectacles, to increase her vision so that she could see the bus/train signs and would recognize faces. She was currently wearing standard RGP corneal lenses.

## Subjective & objective findings

The patient was a 22-year-old female with low vision who was wearing RGP lenses.

● Refraction:			
VOD	S -6.25 C -1.75 @ 60		VA 0.2-
VOS	S -4.25 C -1.00 @ 95		VA 0.15

● VA with her current RGP lenses:			
VOD	BCR 7.60 / S -5.00 / Ø 9.3		VA 0.2-
VOS	BCR 7.65 / S -5.00 / Ø 9.3		VA 0.15

● Keratometry:			
OD	7.60/7.33		regular pattern
OS	7.70/7.35		regular pattern

● **Slit lamp:** examination revealed normal corneas and anterior segment of the eye.

The first lenses ordered and dispensed after first inspection and assessment were:

**Full Scleral:**  
OD Vault 4.37/S-20.00/BCR 7.80/Ø 21.5/SC 13.25/LZ normal  
OS Vault 4.37/S-19.00/BCR 7.80/Ø 21.5/SC 13.25/LZ normal

● Over-refraction:			
VOD	S + 9.00		VA 0.45
VOS	S + 10.00		VA 0.3
VOU	0.5		

With dispensing of the lenses, we also provided the prescription for glasses based on her current over-refraction. The combination of the lens power and the over-refraction would create an image magnification, which should lead to an increase in her ability to read signs, recognize faces, etc.

## 1st follow up visit

Her first follow up visit was after 5 weeks. The patient reported that she was very happy with the results. She could wear the lenses with the hyperopic glasses successfully. With the combination she was able to read the train signs at the station, and for the first time she went to a discotheque with friends. The central fitting and the periphery looked good. The corneas looked clear, and there was no conjunctival impingement.

VOD	with scleral lens	VA 0.45
VOS	with scleral lens	VA 0.3
VOU	with scleral lens	VA 0.5

## 2nd follow up visit

At the second follow up visit after four months, she was still very happy with the result. She was wearing the combination of scleral lenses and glasses quite often: 4 to 5 times a week when she thought she would need them for outdoor activity. The fit of the scleral lenses was still good, both centrally and peripherally. Her corneas and conjunctiva looked unremarkable. Her visual acuities were the same as the last time we had seen her.

## Long-term results

The scleral lenses are renewed by default on a yearly basis. The patient has been using this special low vision aid for more than 15 years now. We see her every 6 to 8 months for regular follow up visits.



## Summary & Discussion

This case illustrated the huge impact scleral lenses can have on patients' lives and on their quality of living. In most cases this concerns the sometimes incredible improvement in vision with scleral lenses that patients can experience when they have compromised corneas. Oftentimes this can result in emotional situations. Eye care providers should be best prepared for this, and may need to find the time in their

busy practices to appropriately handle such situations. This particular case was exceptional, because her visual acuity simply could never exceed the maximum VAs that are reported here because of her bilateral congenital optic nerve coloboma. But with basic knowledge of optics combined with some creativity, scleral lens specialist can really make a difference in some patients' lives.



indication



keywords

# Hand-painted scleral lens

Chrétien Frambach

Small eye appearance | central corneal scar | hand-painted scleral lens | aesthetics

20

Case



Gender:  
Female

Age:  
34



discussion

## Introduction

The patient presented with a shrunken eye OS and a visible central corneal scar. She had been wearing a soft, black-backed iris prosthetic lens with closed pupil and was pretty comfortable with it. The iris color of the lens peeled off very soon, though, leaving just the black backing. It was the second time this had happened. The delivery time of a new soft prosthetic lens is about 6 weeks. Another concern was the ptosis OS because of her shrunken eye.

## Subjective & objective findings

A 34-year-old woman with one eye exhibiting no functional vision (OS, some light perception) came in for a lens fit for aesthetic reasons. The other eye was emmetropic with normal vision. The pupil OS was white and the cornea had vascularised to some degree. The appearance of this eye was the reason for her visit (see slit lamp image OS of the naked eye). The diagnosis was uncertain because she was not a patient in our hospital. The cornea OD is 11.1 mm and the cornea OS is 9.3 mm in diameter. Canthus-to-canthus measurements of both eyes had the same results ODS. Mild ptosis OS was visible.

## Lens Fit

Having had negative experiences with soft painted contact lenses and her small eye diameter, we decided to fit a mini-Misa scleral lens. This lens, with more volume, could also possibly increase her lid aperture OS, decreasing her ptosis. Initial comfort of the lens was very good. The fitting was performed using fluorescein (see fluorescein image OS). A photo was taken of the reference eye (see slit lamp image OD) and measurements were taken of the corneal diameter, using the 'white-to-white' distance. A good color match with the right eye was determined by having the patient pick the best color sample out of our box of hand-painted examples (see image of hand-painted set). We kept the patient involved in the decision process, and, for instance, she wanted the ocularist to put a little bit more 'foxy brown' in the eye color. The mini-Misa lens with the sample eyes were sent to an ocularist. For iris texture, the reference photo was sent with the order as well.

Because of a special sandwich process in manufacturing the lens, the paint of the lens is protected against scratches, resulting in a lens that can last for up to 3 years. We advised her to use an abrasive cleaner and to rinse this off with unpreserved saline. Saline was advised to use for application of the lens as well.

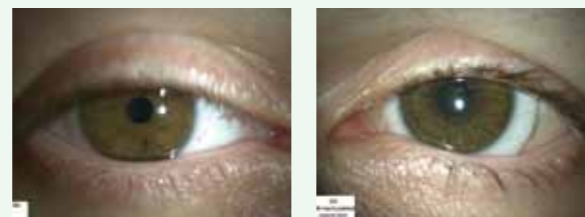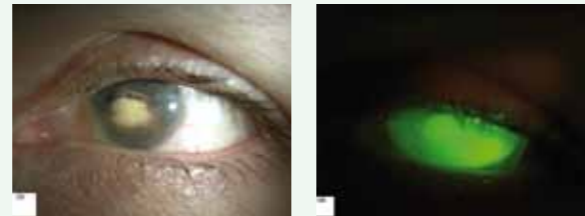
**Mini Misa scleral lens** ordered and dispensed OS:  
OS Vault 2.75/plano/BCR 7.80/Ø 16.5/SC 13.5/LZ normal – Hand-painted custom order.

## 1st follow up

At the first visit the patient was very pleased with the results. She could wear this prosthesis the whole day. The photo of the mini-Misa shows some shadows at the edge, but in real lighting conditions this was not visible and the eye looked very realistic (see slit lamp image OS with hand-painted scleral lens). There was no redness and she mentioned that handling was very easy. The ptosis was not noticeable at this point.

## 2nd follow up

A second visit took place after 6 months of wear. Discomfort as a result of deposits on the lens was a main concern. This could lead to contact lens-induced papillary conjunctivitis, so lens care should be managed carefully to prevent this from occurring. We discussed this and will continue to monitor the condition of the lens at future visits. She comes in regularly at 6 month intervals.



## Summary & Discussion

Fitting hand-painted contact lenses can be both extremely rewarding and very challenging. Lens decentration or tropia can make the end result look quite disappointing. Creating a good color match is essential because patients can be very demanding. Sending a color-matched, hand-painted example from the trial set can give the patient a good idea of what the end result will be. Also, good fitting characteristics will make the lens better tolerated, so the lens fit is therefore quite crucial as well – although vision was not a consideration in this case. A copy of the mini-Misa lens was

sent to the oculist, which is necessary when making a copy in PMMA material. Only PMMA is suitable to be painted. On a healthy cornea this lens might not be a good idea because of anoxia, but for painted lenses this is not an issue. Deposits on the lens remain a concern, though. This could lead to contact lens-induced papillary conjunctivitis, and lens care should be managed carefully to prevent this from occurring as it may lead to limited wearing times or even temporary discontinuation of lens wear.

# Management & Problem Solving

This chapter highlights some of the characteristics of scleral lens fitting as discussed in the last chapter, but focuses more on how to achieve a better outcome if the initial lens fit is not optimal. For instance, the importance of changing the 'haptic portion' of the lens, e.g. the part that rests on the sclera, is emphasised in one of the case reports. Since it is actually the bulbar conjunctiva that is being fit, it is very helpful to evaluate pressure of the lens periphery on the bulbar conjunctiva. Localized areas of the conjunctiva surrounding the limbus can be "whitened" because compression of the lens on the conjunctiva restricts blood flow, which is referred to as conjunctival blanching. A case report with conjunctival redness and staining will illustrate this. Also, changing the right lens diameter can help improve the scleral lens fit as is shown in another case in this chapter.

But a technically successful lens fit alone is not sufficient for successful scleral lens wear. Several other factors, including hygiene, proper lens care, good instructions, and lens handling issues play a crucial role in this.

Chronic allergic conjunctivitis and poor tear condition can be a reason for discomfort and dropouts. Consequent use of artificial tears to treat allergic conjunctivitis in the long-term will improve the eye condition and in the end may result in successful scleral lens wear, as a case in this chapter will show. Another case in this series reports on a patient with blepharitis and reported dry eye symptoms. This probably contributed to his wearing time being limited, but with removal, cleaning and refreshing of solution every 4 hours, the patient can wear the lenses during all waking hours.

An important role for the eye care practitioner in fitting scleral lenses in some cases is to temper the enthusiasm of the scleral lens wearer. Scleral lenses can be so comfortable and the vision so superior to previous correction methods that patients sometimes tend to over-wear their scleral lenses, as one case will show. Most patients also find it a nuisance to have to remove the contacts halfway through the day to refresh the solution. Nevertheless, doing so can be important for eye health in the long term. Regular check ups and emphasis on adhering to the wearing schedule and the cleaning/refreshment regimen seem essential for long-term scleral lens wear.

In another case a patient could not be convinced to comply with the basic lens care rules, including washing hands before lens handling. This may or may not have led to secondary complications such as viral corneal infections. Lens care and hygiene with scleral lenses are at least as important as in normal lens wear, but since scleral lenses are oftentimes used in compromised eyes it may in fact be even more important in scleral lens wear. Also, since vision is usually reduced, the consequences at stake (losing vision potential) seem greater as well.

For elderly patients, and for high hyperopes, manipulating

the lens can be quite challenging. One case shows that a fair amount of persistence in scleral lens fitting sometimes is needed and can pay off. The help of family members with lens handling can also be of pivotal importance for the success of scleral lens wear.

Also, an important task of the eye care practitioner is to inform the patient prior to corneal surgery about the expected outcome. As an illustration, sometimes patients undergoing corneal crosslinking assume that all of their vision problems will be solved with the surgery. Their disappointment can be very intense and emotional when a lens is still needed after the procedure. It is a very important task for the eye care provider to instruct the patient about the likely need for lenses (often scleral lenses) after procedures such as corneal crosslinking, corneal transplants and also intrastromal rings.

Finally, a case report on managing a complication of keratoconus – which is where this case series began with, as the number one indication for scleral lens fitting. Corneal hydrops is a fairly rare condition in keratoconus patients, which can be very dramatic to the clinician and the patient. This case reports describes the occurrence of a hydrops, and how to manage it with regards to scleral lens wear. Hydrops is known to resolve on its own, but the epithelial edema may worsen from wearing a scleral lens. Once the edema resolves, the patient can resume scleral lens wear.



Scleral Lens Case Report Series - Management & Problem Solving



indication



keywords

21

Case



Gender:  
Female

Age:  
59

# Scleral lens refit with conjunctival redness/staining and haze in a PMD patient

Jaap van Blitterswijk, Cristian Mertz, Marjolijn Bartels

Pellucid marginal degeneration (PMD) | smaller diameter scleral lens | conjunctival redness and staining | haze

## Introduction

A PMD patient presented for a scleral lens refit for her right eye. Due to the peripheral location of the ectasia on the cornea, a corneal transplant is not an attractive treatment option. A toric intraocular lens implantation or corneal wedge resection were suggested by her ophthalmologist as last resort surgical options. But prior to that, a last attempt to fit contact lenses was undertaken.

## Subjective & objective findings:

A 59-year-old female patient was diagnosed with PMD. Her visual acuity OS is low as a result of a Herpes Simplex infection. She had tried several RGP corneal and scleral lenses. Her last pair of lenses was almost two years old: a toric Misa Full Scleral lens: T1 Vault 3.50 / S -5.50 / BCR 7.20 / Ø 20.0 / SC 13.5 / LZ Toric. The patient reported that this lens was uncomfortable, and the wearing time was limited to a few hours before the lens wettability would degrade and vision would get hazy.

### Refraction:

VOD	cc	S 0.00 C -1.75 @ 17	VA 0.02
		with pinhole glasses:	VA 0.25
VOS	cc	S +1.50 C -1.50 @ 118	VA 0.55
		with pinhole glasses:	VA 0.7

● **Corneal topography:** see Oculus Pentacam topographical image OD. Note the classic 'kissing dove' pattern.

● **Slit lamp:** Exam OD showed corneal thinning inferiorly; the central corneal thickness was adequate and clear - see Ocular Pentacam Scheimpflug image OD. OS evaluation showed a clear, healthy cornea. Conjunctival redness and staining were visible at the edge of the scleral lens superior-temporally at the time of examination.

A refit with a new Misa Mini Scleral lens was considered rather than continuing with the current full size Misa Scleral Lens. The lens parameters of the first trial lens were:

**Mini Misa Scleral lens:**  
OD Vault 4.00/S -3.50/BCR 7.20/Ø 16.5/SC 13.5/LZ wide

This lens was dispensed after first inspection and assessment. It yielded a good lens fit, and a next appointment was scheduled for 4 weeks from this visit.

## 1st follow up visit

Although comfort of lens wear had much improved, but decreased wettability and haze was still an issue after a few hours of lens wear. The visual acuity was VODcc 0.3. The lens fit was assessed as optimal, and no conjunctival irritation was observed. Slit lamp examination further revealed that the lens surface indeed exhibited poor wettability and deposition.

We advised the patient to continue wearing this lens, but to clean it at night with an extra-mild non-ionic cleaner. However, she was not used to having an extra cleaner with her old lenses, so she failed to use one with the new scleral lens we provided. We also advised her to apply the lens with a higher viscosity solution and to re-apply the lens every 4

hours with new solution for extra wettability. The next check up was scheduled in two weeks.


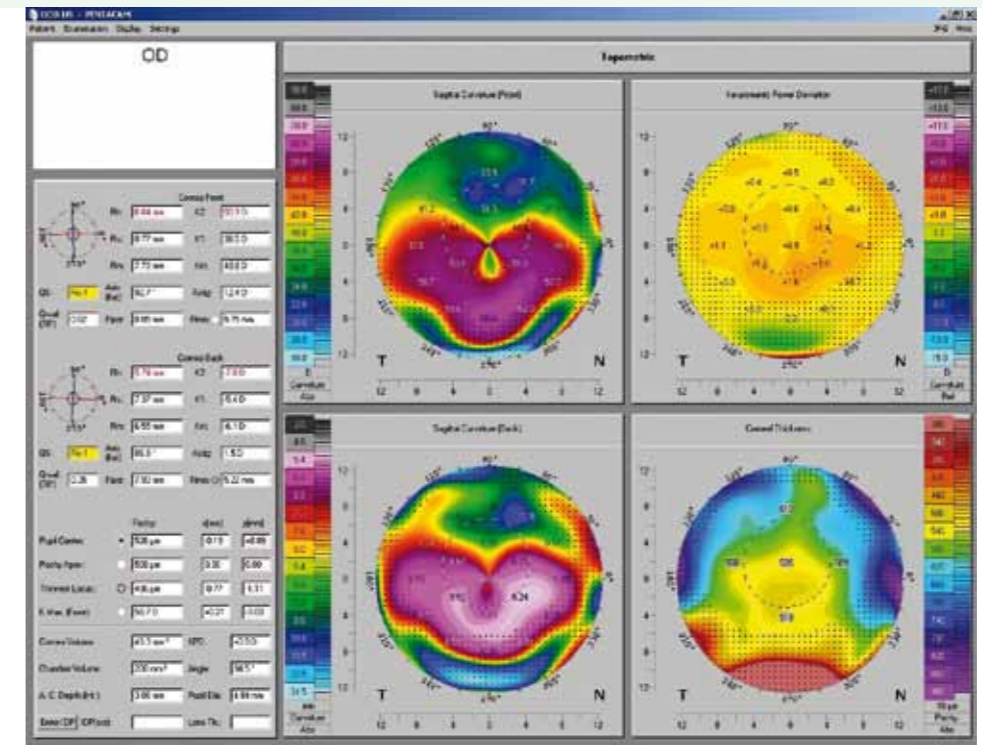
## 2nd follow up visit

**Over-refraction:**  
VOD S 0.00 C -1.00 @ 180 VA 0.3

After two weeks, the wettability problems seemed to have vanished. She could wear the lens during the day without wettability issues. There were no signs of conjunctival irritation at this point and her visual acuity was good. Her next check up was scheduled for 3 months from this visit.

## 3rd follow up visit

After two months the patient returned. This was earlier than the scheduled check up. She was experiencing the same problems with wettability and haze as with the 1st follow up. After consulting with the manufacturer, a lens was ordered in an other type of material (Paragon HDS), with improved wettability properties. The rest of the parameters remained the same. At the follow up four weeks later, the patient was again very satisfied.



## Summary & Discussion

PMD patients are extremely difficult to correct with corneal lenses due to the peripheral location of the corneal ectasia. For that reason, even a corneal transplant is not a very attractive alternative, as in this case.

While scleral lenses seem to be the most optimal option in this case, even a toric full scleral lens was not satisfying. The literature has indicated that the larger the diameter of the scleral lens, the greater the need is for a toric scleral lens design. This may be bypassed in some cases by going smaller. A 16.5mm lens rather than a 20.0mm lens worked in this case: no toric lens design was needed and the conjunctival irritation disappeared.

'Haze' or 'fogging up' in scleral lens wear is not uncommon. Three different factors most likely contribute to this. First of all, the oxygen permeability of the lens should be monitored to prevent edema. High Dk materials, thinner lenses are key points in this as well as a reduction in tear clearance as

the tear layer also acts as an additional barrier for oxygen to be delivered to the cornea. Obviously, the haze remains after lens removal if hypoxia is the cause. Secondly, 'toxic waste' behind the lens resulting from solution preservatives and inflammatory cells can cause a mild to severe toxic reaction to the epithelium, which may make it 'hazy'. This also remains after lens removal. Thirdly, debris behind the lens and wettability can be a big issue. Debris behind the lens is usually managed by instructing patients to take out the lens at least once a day and to clean and refill the lens before re-application. Reduced lens surface wettability can be a serious limitation in scleral lens wear and should be taken very seriously as it may be the difference between success and failure of the lens modality – even if the lens fit is perfect. Better cleaning and changing the application solution, as well as reconsidering the lens material, can all help alleviate this problem. Some even advocate using a cotton swap to 'clean the lens surface like a windshield wiper' with the lens in vivo.



figures



discussion



indication



keywords

22

Case



Gender: Female

Age: 33

# Keratoconus, deep anterior lamellar keratoplasty & allergic conjunctivitis

Cor van Mil

**Keratoconus** | **Deep Anterior Lamellar Keratoplasty (DALK)** | **toric scleral lens fit** | **chronic allergic conjunctivitis** | **artificial tears en treatment of allergic conjunctivitis**

## Introduction

Contact lens fitting on an irregular corneal surface is one of the most challenging of all lens fits. But even if severely irregular, a rigid contact lens is required to provide good eyesight. When corneal contact lenses cannot provide comfort and good vision, scleral lenses might be the solution. This case reports on a scleral lens fitting in a patient who had keratoconus OD and DALK OS, complicated by signs of chronic allergic conjunctivitis.

## Subjective & objective findings

A 33-year-old female was seen at our eye clinic who had keratoconus OD and DALK after keratoconus OS. Corneal contact lenses and piggyback lenses were unsuccessful because of intolerance. Correction with glasses was also unsatisfying and caused problems with computer work.

**Medication:** Fluormetholon (FML, Allergan Inc)

● **Refraction:**

VOD	S -2.00 C -2.50 @ 75	VA 0.7+
VOS	S -3.75 C -3.00 @ 110	VA 0.4+

● **Keratometry:**

OD	7.46 mm @ 137 / 7.79 mm @ 47
OS	7.48 mm @ 20 / 8.01 mm @ 110

● **Corneal topography:** see Oculus Pentacam images OD and OS.

● **Pachymetry:**

OD	443 microns, topography indicates: keratoconus
OS	589 microns, topography indicates: irregular corneal astigmatism

● **Slit lamp:**

OD	Clear cornea, thinning, keratoconus
OS	Clear cornea, status after DALK

See Oculus Pentacam Scheimpflug image OS, with the transition from transplant to old cornea visible.

● **Schirmer II:**

OD	5 mm
OS	10 mm

**The first attempt to fit corneal RGP lenses resulted in this prescription:**

OD	BCR 7.80 / 7.40 S -3.00 dia 9.6
OS	BCR 8.00 / 7.60 S -3.00 dia 9.6

**The over-refraction and vision with these lenses was:**

OD	S 0.00 C -0.75 @ 85	VA 0.95
OS	S -1.00 C -0.75 @ 90	VA 0.7

The slit lamp findings showed a good lens fit, but the patient reported an absolute intolerance of the lenses.

Advice is to stop using FML because of the risk of high intraocular pressure, to prescribe artificial tears and to fit scleral lenses.

**A few weeks after this, scleral lenses were fitted:**

**Misa Full Scleral:**  
 OD Vault 3.25/S -2.00/BCR 7.80/Ø 20.0/SC 13.5/LZ normal  
 OS Vault 3.50/S -2.00/BCR 7.80/Ø 20.0/SC 13.5/LZ normal

**The over refraction with these lenses was:**

OD	S -1.50	VA 1.0
OS	S -3.00	VA 0.8

The lenses ordered were:

**Misa Full Scleral:**  
 OD Vault 3.25/S -2.00/BCR 8.10/Ø 20.0/SC 13.5/LZ normal  
 OS Vault 3.50/S -3.50/BCR 8.10/Ø 20.0/SC 13.5/LZ normal

## 1st follow up visit

After 4 weeks of lens wear, the patient reported maximum wearing time of 5 hours and dizziness with the lenses. Lens wear made the eyes feel uncomfortable. She reported having problems handling scleral lenses. During this consult, the scleral lenses were applied and checked. The visual acuities with the lenses were: VODcc 0.9 and VOScc 0.7. Slit lamp findings revealed a small apical clearance on the right eye, a good fit on left eye and a dry scleral lens surface. An allergic conjunctivitis ODS was diagnosed.

At this point it was advised to the patient to a change of care system to Synergi (Sauflon), and Olopatadine (Opatanol, Alcon) and Hyaluronate 0.15% (Hyabak, Thea Farma) were prescribed.

## 2nd follow up visit

The next consult took place 5 weeks after the last visit. This time the wearing time was 2 hours maximum. Patient reports discomfort at the temporal sclera.

OD	S +0.50	VA 0.9
OS	S +0.25 C -0.75 as 65	VA 0.9

To improve the peripheral fit, we ordered toric scleral lenses:

**Misa Full Scleral T1:**  
 OD Vault 3.50/S -0.50/BCR 8.30/Ø 20.0/SC 14.0-13.5/LZ toric  
 OS Vault 3.75/S -3.50/BCR 8.10/Ø 20.0/SC 14.0-13.5/LZ toric

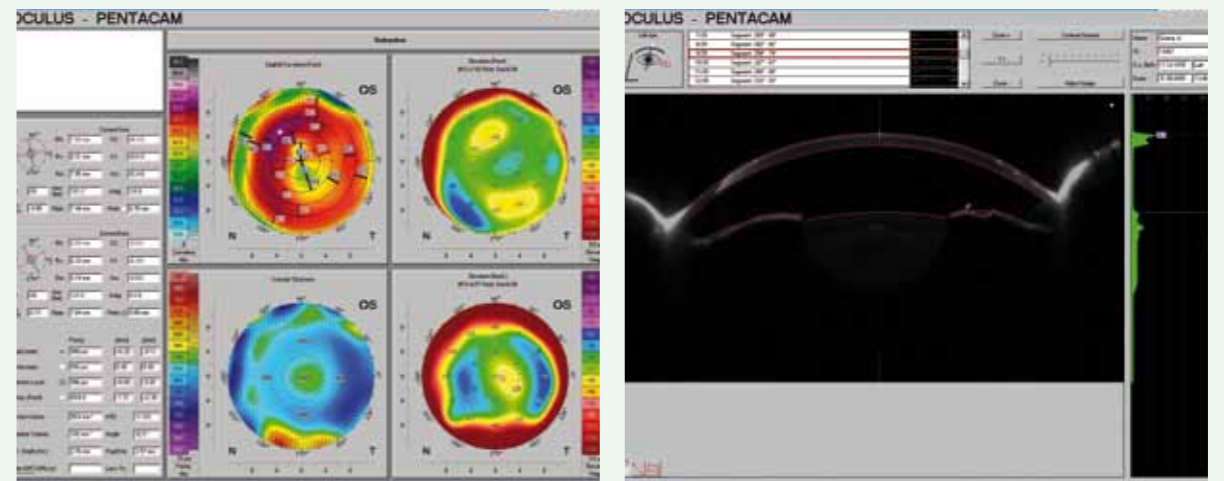
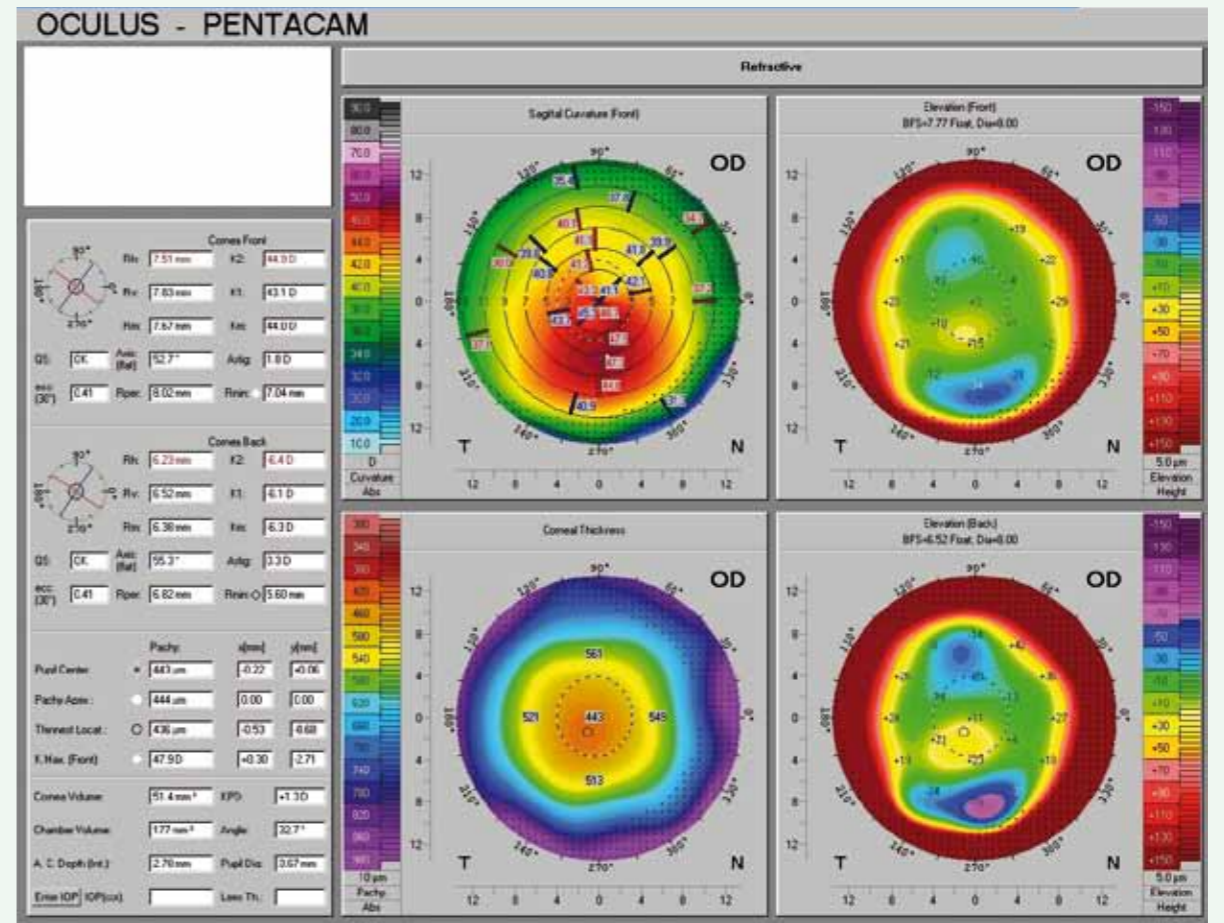
## 3rd follow up visit

This consult took place 4 months after the previous visit. The wearing time was up to 8 hours now with little discomfort. Debris under the scleral lenses was visible. Chronic allergic conjunctivitis ODS was diagnosed.

Ketotifen (Zaditen Unidose) 5 x per day 1 drop ODS and Vismed wash 2 x per day 1 drop ODS were prescribed. It was also advised to apply the scleral lenses with Carboxy Methyl Cellulose (Celluvisc unidose).

## 4th follow up visit

This consult occurred 2 months after the last visit. Wearing time of the scleral lenses was up to 15 hours, lenses felt comfortable.



## Summary & Discussion

The best option to correct vision in an irregular cornea is RGP contact lenses. In keratoconus, we find that over 50% of patients have an atopic or allergic constitution. Because of a bad tear condition and allergic conjunctivitis, wearing RGP corneal lenses can be very difficult and often is impossible.

Fitting scleral lenses is the next step in correcting the irregular cornea because scleral lenses have many advantages compared to corneal lenses: there is no touch on the sensitive cornea and the edges of the lenses cause less eyelid problems due to their large diameter. Still, the chronic allergic

conjunctivitis and poor condition of the tears is reason for discomfort and dropouts sometimes. Consequent use of artificial tears en treatment of allergic conjunctivitis in the long-term will improve the condition of the eyes and in the end may result in a successful scleral lens fitting.



figures



discussion



indication



keywords

23

Case



Gender: Male

Age: 69

# Keratoconus & the need for managing dry eye symptoms

Jaap van Blitterswijk, Cristian Mertz, Marjolijn Bartels

Keratoconus | RGP lenses | hybrid lenses | blepharitis | dry eye | lens cleaning & re-insertion

## Introduction

This case reports on an unsatisfied RGP and hybrid lens-wearing keratoconus patient. New scleral lenses were tried for this patient to improve his visual performance and visual function and to avoid a deep anterior lamellar keratoplasty (DALK) as a last resort.

## Subjective & objective findings

A 69-year-old man had been diagnosed with keratoconus years ago. For his right eye he was wearing an RGP lens (Keratoconus Anatomic Microlens BV: BCR 6.60 S -6.75 Ø 9.3 eccentricity 0.9 and 0 in one quadrant, focon III 2 material) and for his left eye he was wearing a hybrid contact lens (Synergeyes KC BCR 5.90 S -15.50 Ø 14.5 Skirt 7.90 with an pafufocon D center and hemiberfilcon A skirt). The patient had an extensive history of wearing different RGP and scleral lenses of different design, but none were to his satisfaction. The wearing time of any of these lenses was limited. To compensate for his dry eye symptoms and to extend the wearing time as much as possible, he had been using artificial tears (Hylocare, Ursapharm).

He was currently experiencing severe dry eye symptoms after a number of hours of lens wear. Upon removal of his current lenses he was experiencing a red and painful right eye. Only after a few days of no lens wear the eye recovered sufficiently enough to resume lens wear. The dry eye symptoms seemed at least partly related to a blepharitis, which was treated with daily eyelid hygiene (Blephaclean, Spectrum Thea).

Because the dry eye treatment with eyelid hygiene and artificial tears had limited success, one final attempt was made to try a new scleral lens. If it was not desirable, a deep anterior lamellar keratoplasty (DALK) would be considered as a last resort. The patient was not quite ready for the surgical option with the donor tissue and wanted to try scleral lenses for the last time. First the left eye was fitted with a scleral lens, as the right eye with the quadrant specific RGP lens was doing relatively well at that moment.

● **Refraction:**  
VOD cc 0.95 VA could not be improved  
VOS cc 0.15 S -3.00 C -1.25 @ 180 VA 0.5

● **Corneal topography:** see Oculus Pentacam image OS

● **Slit lamp:** OD Vogt's striae, apical opacities, no corneal staining. RGP lens fit: acceptable.  
OS Vogt's striae, apical opacities, no corneal staining. See Oculus Pentacam Scheimpflug image OS.

The first lens ordered and dispensed after first inspection and assessment was:

**Misa Full Scleral:**  
OS Vault 4.00/S -4.00/BCR 7.80/Ø 20.0/SC 13.5/LZ normal

## 1st follow up visit

At the first visit, two weeks after dispensing, lens comfort was described as suboptimal. The lens could be worn for only a limited amount of time. Visual acuity subjectively was rated as good, although it was sometimes somewhat hazy just after lens application.

Visual acuity OS with this lens was recorded at VA 0.8. The lens fit appeared to be acceptable, although the central corneal clearance was fairly low. This would be monitored and checked at the next visit. The patient was advised to continue lens adaption maximizing the wearing time according to the described schedule, and necessarily remove and re-apply the lenses with fresh solution.

## 2nd follow up visit

Six weeks after the previous visit, the patient was much more positive about the left eye scleral lens' comfort. The lens could be worn 2x 5 hours per day, and the patient reported that lens comfort was actually much better than that of the RGP lens OD. Subjectively the visual acuity continued to be good. The central lens clearance was still fairly low but considered acceptable. Increasing the vault did not seem a good option because it could potentially decrease the visual acuity.

## 3rd follow up visit

At the six-month follow up visit, the patient reported comfort issues with his right RGP lens. There were no complaints with his left eye scleral lens: comfort and vision were reported to be good. Slit lamp evaluation revealed deep central corneal staining OD. He was advised to cease lens wear OD to let the cornea recuperate and to follow up with a scleral lens fit OD.

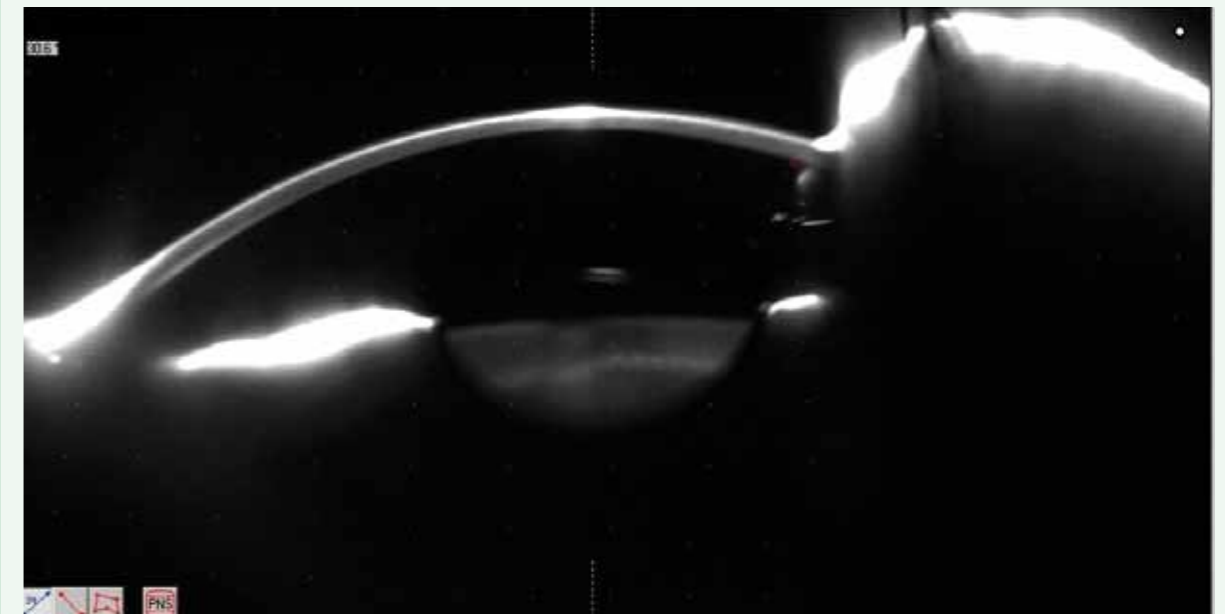
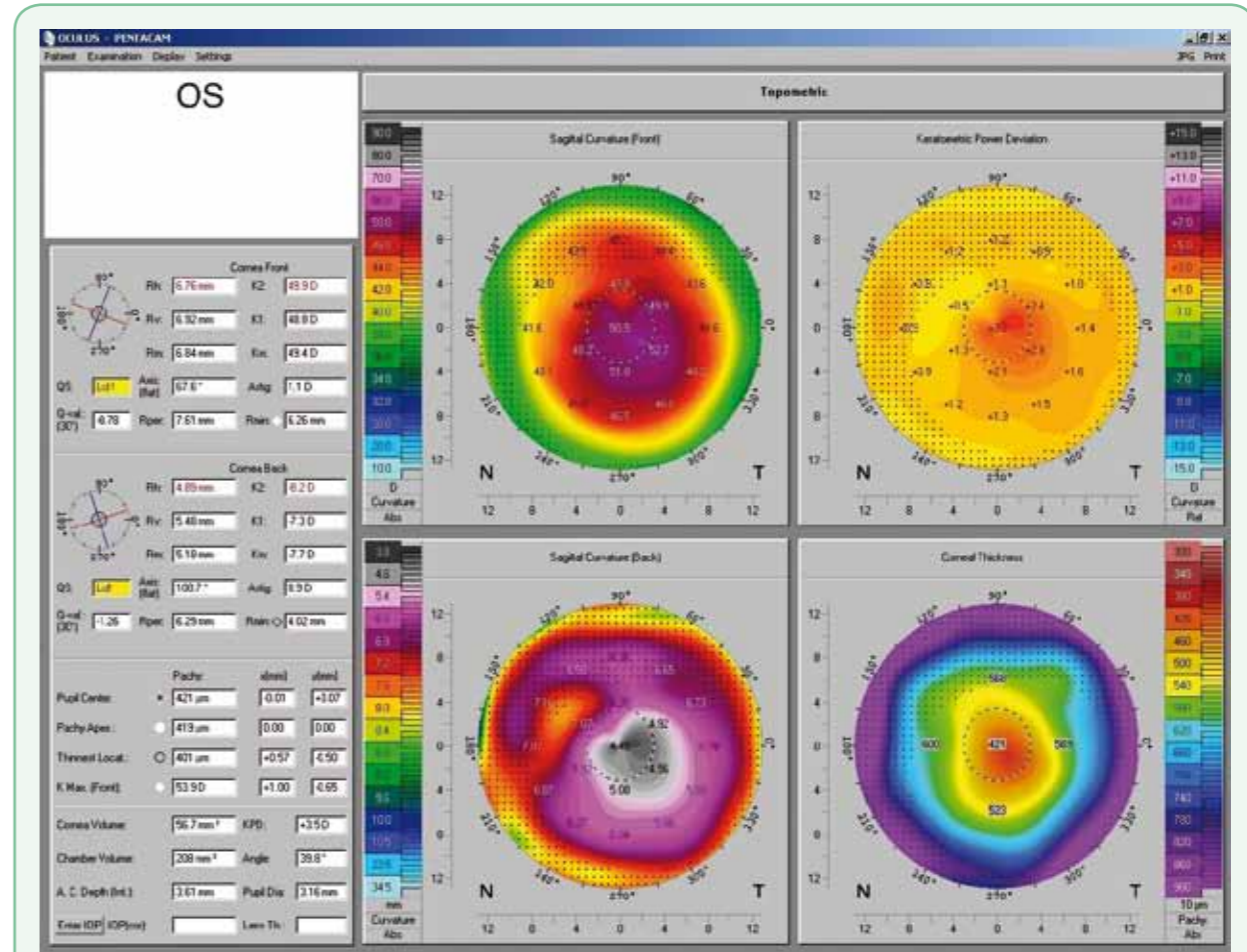
The first lens ordered and dispensed after first inspection and assessment was:

**Misa Mini Scleral:**  
OD Vault 3.75/S +0.25/BCR 7.80/Ø 16.5/SC 13.5/LZ wide

A smaller diameter was chosen for the right eye to minimize the influence of the lens on the conjunctiva (previously this smaller diameter MISA lens was not yet available).

## Follow up visit 6 weeks after OD scleral lens fit

The right lens was reported to be even better than the left lens in terms of lens comfort. In the left eye we could see more influence of the lens on the conjunctiva, resulting in light suction inferiorly. Still the LZ fit well and we could not improve the lens fit. Wearing time was pretty much all day long ODS. He did have to remove the lenses every 4 hours to refresh the solution before re-applying. Failing to do so resulted in discomfort/irritation and the eyes becoming red. Subjective visual performance continued to be good. Objective vision was: VODcc 0.9 / VOScc 0.8. Due to the history of problems, we decided to shorten the follow up period to 2 months.



## Summary & Discussion

This case reports on an unsatisfied RGP and hybrid lens-wearing keratoconus patient. It proved that with the right support, the scleral lenses that were fitted outperformed his current, sophisticated, quadrant specific RGP and state-of-the-art hybrid (with an RGP center and a soft skirt) contact lenses. The patient has blepharitis and reported dry eye symptoms. This probably contributes to his limited wearing time being limited, but with removal, cleaning and refreshing of solution every 4 hours the patient can wear the lenses

during all waking hours – which is often a necessity in advanced keratoconus patients. This shows that in addition to a successful technical lens fit, management of the patient can be of pivotal importance to make the whole scleral lens experience a success.



figures



discussion



indication



keywords

24

Case



Gender: Male

Age: 56

# Vision improvement and blanching in a keratoconus patient

Koen Brands

**Keratoconus** | corneal erosion | RGP lens discomfort | conjunctival blanching | scleral curve alteration

## Introduction

This patient was diagnosed with keratoconus OD. His current RGP lens was riding high and had caused a corneal erosion due to bearing centrally. He was experiencing very poor visual acuity OD and discomfort while wearing his RGP lens. His optician cannot deliver scleral lenses.

## Subjective & objective findings

Male, 56-years-old, diagnosed with diabetes. Other than the keratoconus, his ocular history is clear. No abnormalities were observed OS.

### Refraction:

VOD no refraction possible VA 4/300  
VOS cc 0,8 S +1,25 C 0,75 @ 125 VA 1.0

### Corneal topography: see Oculus Pentacam image OD.

### Slit lamp: Micropunctate corneal staining visible around the top of the cone.

### Misa Full Scleral T1: Vault 4.50 / S -2.00 BCR 7.80/Ø 18.5/SC 13.5-13.0/LZ normal

The lens demonstrated no touch (sufficient corneal clearance). Over refraction was: OD S + 1.75 VA 0.9-. Based on this, the parameters of the ordered scleral lens were:

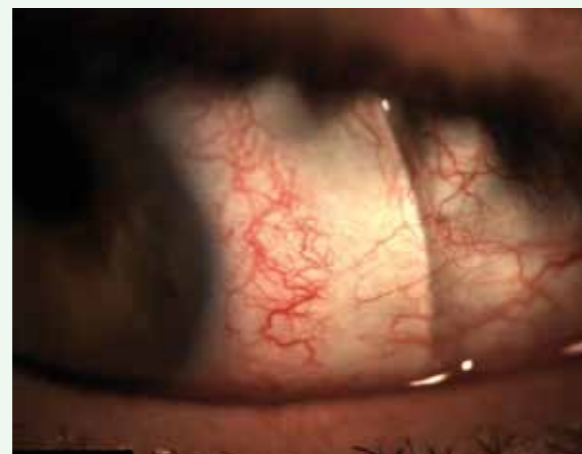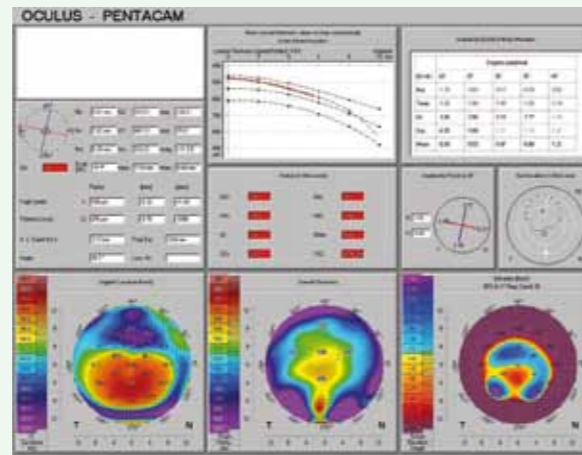
### Misa Full Scleral T1: Vault 4.50 / S -0.25/BCR 7.80/Ø 18.5/SC 13.5-13.0/LZ normal

Delivery and instruction went well. Patient could remove and insert the lens by himself. Refraction after 4 hours of wearing time: OD S + 0.00. VA 0.8+. Slit lamp findings: some blanching of the conjunctiva, but within acceptable range (see slit lamp image). Planned to monitor blanching at the next follow up visit.

## 1st follow up visit

The patient returned for his first follow up visit after 1 week and was very satisfied. His vision was improved and he rated the comfort as 'good'. Over refraction was: OD S +0.50 VA 0.8+. Some blanching was still visible upon slit lamp examination, and the lens centered well with no central touch (e.g. adequate corneal clearance). The micropunctate staining had diminished substantially.

The patient reported wearing the scleral lens with good comfort. To reduce the blanching, the scleral curve was changed from 13.5 mm to 14.0 mm to relieve pressure on the conjunctiva.



New lens:

### Misa Full Scleral: Vault 4.50 / S +0.25/BCR 7.80/Ø 18.5/SC 14.0/LZ normal

## 2nd follow up visit

Comfort and vision were reported to be good after 1 week of wearing this new lens. Over refraction revealed: OD S +0.00 VA 0.8+. No blanching was seen at this visit and the corneal staining had resolved.

## Summary & Discussion

This case illustrates that in some cases, corneal RGP lenses simply cannot supply adequate comfort to restore vision, which is often the case in advanced keratoconus. In addition, the central corneal staining was a concern, as new research seems to indicate that stress on the cornea such as that caused by mechanical pressure on the top of the cone by a RGP lens should be avoided as much as possible to avoid corneal scarring.

This case also highlights the importance of fitting the correct 'haptic portion' of the lens, e.g. the part that rests on the sclera. One of the best clinical methods to evaluate this scleral lens landing zone is to look at the blanching of the conjunctival vessels. Localized pressure can cause a local 'whitening' on the conjunctiva, described as blanching, as shown in the slit lamp image in this case report. By alleviating the scleral landing zone, in this case by choosing a flatter scleral curve, the blanching can be overcome.



discussion



indication



keywords

25

Case



Gender: Female

Age: 65

# Keratoconus, ptosis & the importance of compliance

Cristian Mertz, Jaap van Blitterswijk, Marjolijn Bartels

**Keratoconus** | wearing time | solution refreshment | compliance

## Introduction

This patient was diagnosed with bilateral keratoconus (OD>OS) and also had a prominent bilateral ptosis, with the lid margins surpassing the superior pupil margins. The patient was currently wearing RGP lenses and was experiencing vision problems. The ophthalmologist requested a scleral lens fitting to improve acuity and possibly prevent progression of the ptosis.

## Subjective & objective findings

A 65-year-old woman with bilateral keratoconus had a prominent bilateral ptosis, with the lid margins covering the superior pupil margins. She had insufficient visual acuity with her current RGPs, the parameters of which were unknown. The patient was healthy, used no medications and had no allergies.

### Refraction:

VOD S -3.00 C -5.25 @ 45 VA 0.60  
VOS S plano C -1.25 @ 125 VA 0.80

### Corneal topography: see Microlens topographer images OD and OS (with keratometric values overlay in mm).

### Slit lamp: OD Vogt's striae, otherwise clear cornea. Ptosis past pupil margin. OS Clear cornea. Ptosis past pupil margin. Palpebral fissure ODS 8 mm.

The first trial lenses were:

### Mini Misa Scleral: OD Vault 3.00/S plano/BCR 7.80/Ø 16.5/SC 13.50/LZ Normal OS Vault 3.00/S -1.50/BCR 7.80/Ø 16.5/SC 13.50/LZ Normal

This pair of lenses was ordered and dispensed after first inspection. The fitting was acceptable and the patient left using the lenses.

## 1st follow up visit

The patient had been wearing the Misa lens for 1 week at this visit. The comfort during lens wear was fine, the patient was able to wear the lenses for a full day without complaints. The lenses did not have to be removed to refresh the solution. The vision had improved in comparison with the RGPs. The palpebral fissure appeared larger.

### Over-refraction:

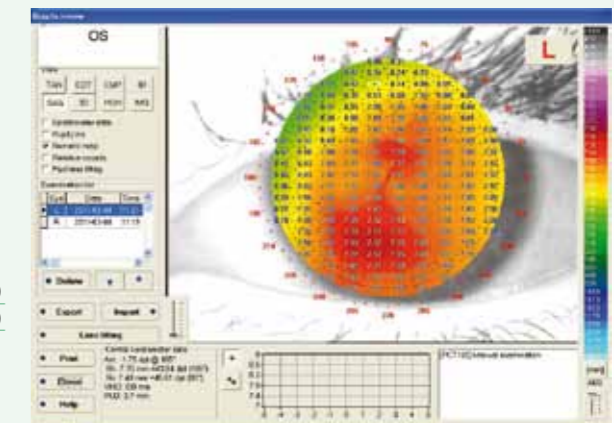
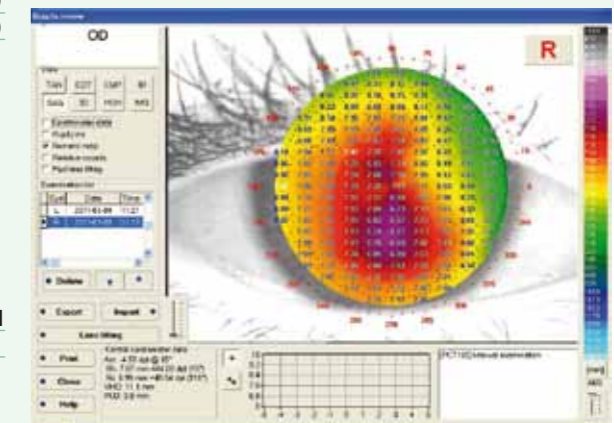
OD S +0.50 VA 0.50  
OS S -0.25 VA 1.00

Palpebral fissure ODS 10mm

The Misa Scleral fit was good. It was easy to manually rotate the lens and no blanching appeared upon slit lamp examination. The conjunctiva and cornea looked healthy. We explained the importance of solution refreshment on time. The patient agreed to not wear the lenses not longer than advised and to refresh the solution halfway through the day.

## 2nd follow up visit

The patient wore the lenses each day from waking to sleeping. Now and then irritation would occur, but this would subside once the solution had been refreshed. Subjective vision was excellent. We reeducated the patient about the importance of timely solution refreshment and abiding to the maximum wearing time. She again agreed to comply. Revision was advised in 6 months.



## Summary & Discussion

In this case we see a common problem with scleral lenses: poor compliance to wearing time guidelines and irregular solution refreshment. Due to high wearing comfort, most patients will exceed recommended wearing times (if the comfort is more than sufficient, why remove the contacts and suffer visual acuity loss?). Most patients also find it a nuisance to have to remove the contacts halfway through the day to

refresh the solution. Nevertheless: this can be important for eye health in the long term. Regular check ups and emphasis on adhering to the wearing schedule and the cleaning/refreshment regimen seem essential for long-term scleral lens wear.



discussion



indication



keywords

26

Case



Gender: Male

Age: 26

# Keratoconus, metamorphopsia, hygiene

Edmond A. Smit

**Keratoconus** | **metamorphopsia** | **vision improvement** | **hygiene** | **hand washing**

## Introduction

This patient was a professional truck driver who was diagnosed with keratoconus a number of years ago. His visual acuity was still reasonable, but he reported metamorphopsia ODS and he failed his vision test for professional drivers license renewal.

## Subjective & objective findings

The patient was a 26-year-old male truck driver with suboptimal vision and keratoconus grade 2 ODS.

- Refraction:**

VOD	S +4.75 C-5.25 @ 90	VA 0.8
		with metamorphopsia
VOS	S +4.75 C-5.75 @ 108	VA 0.6
		with metamorphopsia
- Keratometry:**

OD	Radii 6.58 / 5.70	irregular pattern
OS	Radii 6.20 / 5.89	irregular pattern
- Slit lamp:** examination revealed clear corneas and mild keratoconus ODS.

The following corneal RGP lenses in a keratoconus design were ordered:

OD	BCR 6.40 / S -7.00 / Ø 9.4
OS	BCR 6.50 / S -7.00 / Ø 9.4

Vision with these lenses was OD and OS 0.7 without metamorphopsia. He passed his driving test.

## Follow up visits

After initially showing good visual acuities - up to 0.9 OD and 0.8- OS - and with a satisfied patient, the cornea started to exhibit an increasing amount of central epithelial staining. A corneal RGP lens refit was considered about 1.5 years after the initial fit, but it seemed that the limits with corneal lenses had been reached. His corneal radii had progressed to 6.25 / 5.30 mm OD and 6.20 / 5.00 mm OS. At this point a scleral lens fit was considered to bridge over the irregular cornea.

The scleral lenses ordered and dispensed after first inspection and assessment were:

**Full Scleral:**  
 OD Vault 4.27/S + 2.25/BCR 7.80/Ø 20.5/SC 13.25 LZ normal  
 OS Vault 4.27 /S +1.25/BCR 7.80/Ø 20.5/SC 13.75/LZ normal

- Over-refraction:**

OD	0.00	VA 1.0
OS	0.00	VA 0.85

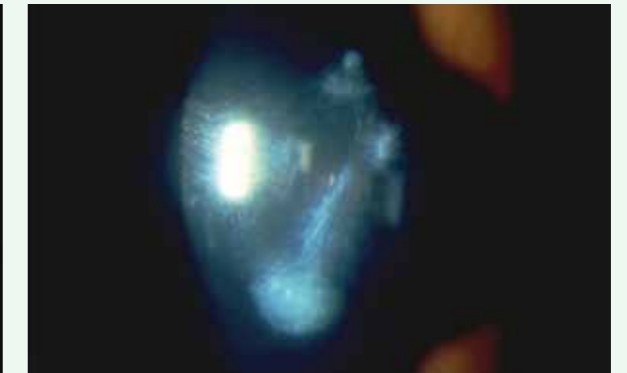
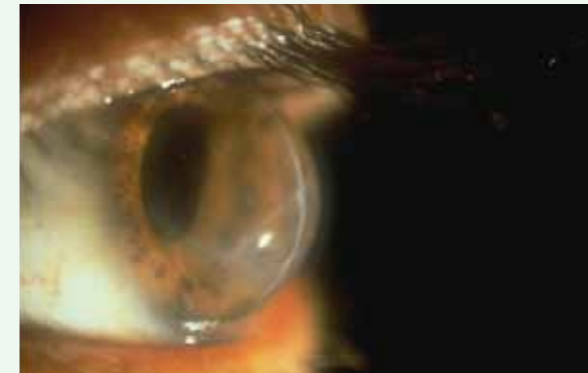
He could wear these scleral lenses without any problems all day long.

## Follow up visits

The patient had been wearing these scleral lenses for years, continuing his work as a truck driver. However, the patient was not very compliant with hygienic care while handling his lenses. We had warned him on several occasions how important proper lens care and hygiene is. In the meantime, he developed a number of cases of epidemic keratoconjunctivitis and a Herpes Simplex infection. He was required to discontinue lens wear each time the Herpes Simplex recurred, which meant he could not work at those times. It took a while, but it now appears clear to the patient that it is important to actually wash hands when handling the lenses. The Herpes infection resulted in a large scar over his left cornea.

We refitted the patient with a pair of Mini Misa scleral lenses with a slightly smaller diameter (16.5 mm). His visual acuity remained largely the same, despite the progression of the keratoconus and the scar, at 0.85 OD and 0.8 OS.

The patient now uses only preservative-free lens solutions. These lenses are still successfully worn. We see him at six months intervals, and every year we renew the lenses.



© Bausch + Lomb image library, courtesy of Bausch + Lomb

## Summary & Discussion

It is a given that vision improvement for the irregular cornea is probably the number one indication for fitting scleral lenses worldwide. In this particular case, the actual VA on the chart was acceptable, but the metamorphopsia due to the keratoconus caused his vision to be of such low quality that he failed his vision test for a professional truck driver. Corneal RGP or scleral lenses can resolve this. But why would an eye care practitioner fit a scleral lens rather than a clinically well-proven, regular rigid gas permeable lens?

First of all, the cornea, which is one of the most sensitive parts of the human body, is bypassed as a bearing area with scleral lenses. The sclera exhibits a very low sensitivity, which makes it very suitable for lens bearing. So while at first glance choosing scleral lenses may be counterintuitive because of size, scleral lenses are in fact experienced as very comfortable. When first exposed to a scleral lens, patients almost without exception express their positive excitement about the comfort of lens wear.

Scleral lenses do not touch the cornea, and therefore result in little or no corneal distortion (e.g. corneal warpage) or mechanical corneal staining. In the Collaborative Longitudinal Evaluation of Keratoconus (CLEK) study in the United States, 1209 keratoconus patients were observed over a period of 8 years at several different sites. Results from the CLEK study show that scar formation in keratoconus may lead to a loss in contrast sensitivity, which may create vision problems. This is especially a concern because keratoconus patients already have increased higher-order aberrations, primarily vertical coma, that may result in reduced contrast sensitivity.

Avoiding pressure on the apex of the cornea with contact lenses seems advised. This may be especially true in the case of central keratoconus, since a central scar almost certainly leads to a loss in visual acuity (see two illustrations of central corneal scarring in keratoconus patients, Bausch + Lomb image library - courtesy of Bausch + Lomb). In this case, the corneal staining was no longer considered acceptable with his corneal RGP lenses, and scleral lenses proved to be successful in overcoming this.

However, as stated in earlier cases, a technically successful lens fit alone is not sufficient for successful scleral lens wear. Several factors including hygiene, lens care and lens handling issues play a crucial role in this. In this case the patient could not be convinced to comply with the basic lens care rules, including washing hands before lens handling. This may or may not have led to secondary complications such as the viral corneal infections. Lens care and hygiene with scleral lenses are at least as important as in normal lens wear, but since scleral lenses are oftentimes used in compromised eyes it may in fact be even more important in scleral lens wear. Also, since vision is usually reduced as well, the consequences at stake (losing vision potential) seem larger as well.

Source: Barr JT, Schechtman KB, Fink BA, Pierce GE, Pensyl CD, Zadnik K, Gordon MO, the CLEK Study Group (1999) Corneal scarring in the Collaborative Longitudinal Evaluation of Keratoconus (CLEK) study: baseline prevalence and repeatability of detection. *Cornea*; 18, 34-46



figures



discussion



indication



keywords

# Keratoconus & scleral lens over-wear

Jan Pauwels, Bernard Duchesne and Jean Claude Delcourt

Advanced keratoconus | red eye | over-wear | hypoxia

27

Case



Gender: Female

Age: 38

## Introduction

RGP lenses have been considered the first option by many practitioners when it comes to correcting keratoconus. However, some stages of keratoconus are just too advanced to be fit with corneal RGP lenses, and it also requires more fitting skills. In this stage-four keratoconus patient, a scleral lens was considered as a first lens of choice.

## Subjective & objective findings

The 38-year-old female patient with advanced keratoconus OS>OD reported poor vision in her left eye.

### Refraction:

VOD sc 0.1 S -4.50 C -4.00 @ 100 VA 0.7  
VOS sc < 0.01

No glasses could be worn due to significant anisometropia.

### Corneal topography:

see classic keratoconus topography images (Oculus Pentacam) OD and OS.

### Slit lamp:

examination revealed a clear cornea OD and some corneal scarring OS, with slight pooling of fluorescein on the corneal epithelium due to the irregular corneal surface.

The first lenses ordered and dispensed after first inspection and assessment were:

#### Mini Misa Scleral:

Vault 3.75/S+ 2.75/BCR 7.80/Ø 16.50/SC 13.75/LZ normal  
Vault 3.75/S- 1.00/BCR 7.80/Ø 16.50/SC 13.5/LZ normal

### Over-refraction:

VOD S 0.00 VA 0.9  
VOS S 0.00 VA 0.9

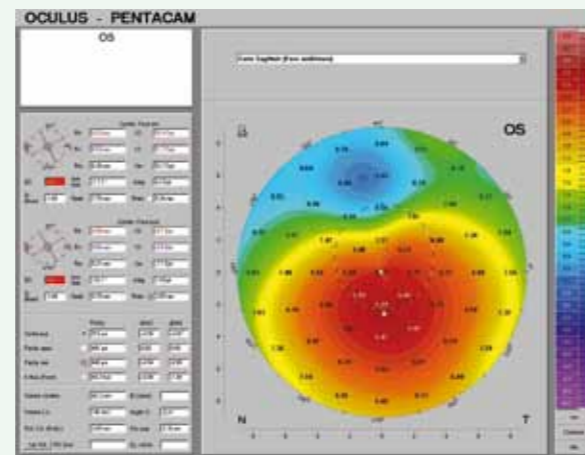
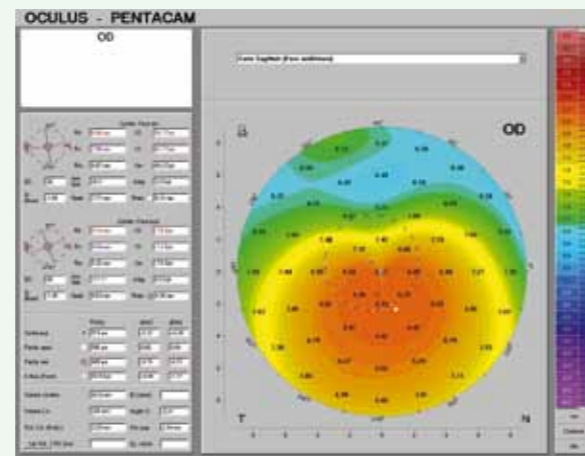
## 1st follow up visit at 1 month

The patient had been very satisfied with the lenses. However, due to the good comfort and long wearing time, he had managed to wear the lenses for 36 hours non-stop after a night out, resulting in an intensely red eye. Also, uveitis had developed.

## 2nd follow up visit at 3 months

The patient was still very satisfied with the lenses and vision was considered optimal. His eyes continued to show a low

degree of redness. He continued to wear the lenses for long wearing times (up to 20 hours a day). He has long working days, and he completely relies on his scleral lenses.



© Photographs: University Hospital Liège (Belgium).

## Summary & Discussion

An important role for the eye care practitioner in fitting scleral lenses is in some cases to temper the enthusiasm of the scleral lens wearer. Scleral lenses can be so comfortable and the vision so superior to previous correction methods, that sometimes patients tend to over-wear their scleral lenses.

The corneal physiology process behind scleral lenses is not yet fully understood. But the tear film exchange behind the lenses is believed to be very limited, while good tear film exchange in corneal RGP lens wear, for instance, is one of the main reasons why RGP lenses very rarely cause infection or even inflammatory related complications. The materials used in modern-day scleral lenses are high to super high Dk, but since scleral lenses are typically thick – especially when compared to RGP corneal lenses – the resulting Dk/t is still limited. In addition, it is believed that the tear film adds an

additional layer that may act as a filter to prevent oxygen from reaching the cornea. Based on that theory, the thicker the tear layer, the lower the oxygen delivery to the cornea. Surely, thinner lenses (for any given material) also provide the best Dk/t. Hypoxic conditions beneath scleral lenses are not hypothetical. Scleral lens practitioners should be urged to look for hypoxic stress on the cornea, including corneal and limbal edema, neovascularization, redness, etc. Limiting wearing time to reasonable periods may be one strategy to prevent or minimize hypoxic conditions beneath the scleral lens. And practitioners should be urged to use the highest Dk/t materials available, with the thinnest lens thickness possible. The latter has its limitations, as thin scleral lenses are more sensitive to flexure and warpage.



discussion

# Scleral lenses in the elderly patient

Jan Pauwels, Bernard Duchesne and Jean Claude Delcourt

Keratoconus | penetrating keratoplasty (PKP) | lens handling | endothelial cell count



indication



keywords

28

Case



Gender: Female

Age: 64

## Introduction

After a bilateral penetrating keratoplasty indicated because of advanced bilateral keratoconus, the patient's vision OD was outstanding (VA 0.9), while OS the VA was limited to 0.05 because of severe irregular corneal astigmatism. A re-plant was considered, but first the option of a scleral lens was explored to overcome the vision problems.

## Subjective & objective findings

A 64-year-old female patient, status after keratoconus OU and long-standing PKP.

### Refraction:

VOD sc 0.7 S -0.50 C -1.00 @ 70 VA 0.9  
VOS sc 0.05 (cannot be refracted – corneal cylinder exceeds 18D of astigmatism)

### Corneal topography:

see Oculus Pentacam image OS.

### Slit lamp:

OD: clear corneal graft  
OS: aging graft, but centrally still clear. Endothelium seems challenged (cell count per mm<sup>2</sup> is 1617), but just enough to allow a scleral lens fit. See Oculus Pentacam Scheimpflug image (top) of the cornea with the graft clearly visible (no lens).

The first lens ordered for the right eye and dispensed after first inspection and assessment was:

#### Mini Misa Scleral:

OS Vault 3.50/S+ 15.00/BCR 8.00/Ø 16.50/SC 13.5/LZ normal

See Oculus Pentacam Scheimpflug image (bottom) of the cornea with the scleral lens in place.

### Over-refraction:

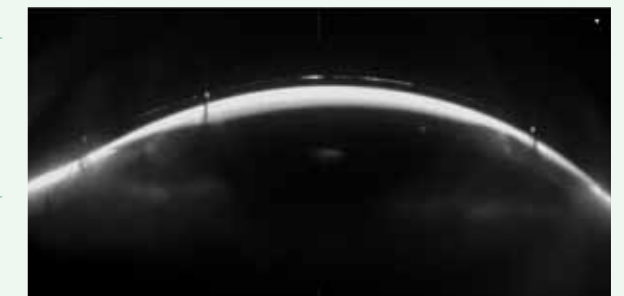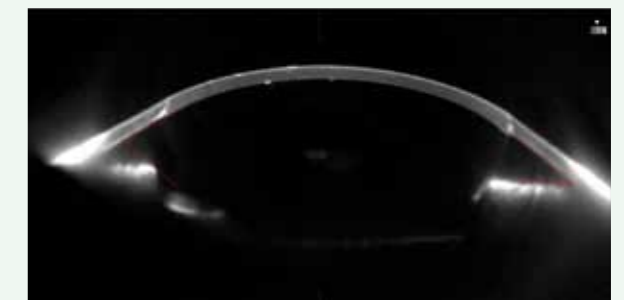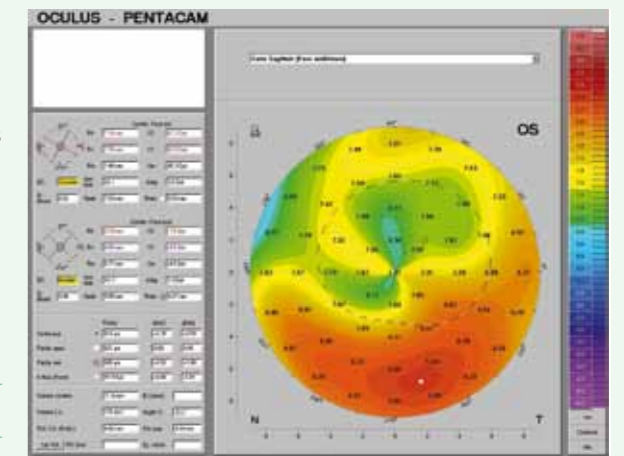
VOS S +1.00 VA 1.0

## 1st follow up visit

At the first follow up visit after one month, the patient indicated that she was struggling with lens handling, presumably challenged by her prescription and her age. She also broke a lens, and scleral lens discontinuation was considered at this point. After discussion and reconsideration, it was agreed upon to give it one more go. The lens was replaced free of charge.

## 2nd follow up visit

At the three-month visit, the patient was much more enthusiastic. She was wearing the lens on a daily basis, and lens handling had become far less complicated. Comfort and visual acuity were very much to her liking.



© Photographs: University Hospital Liège (Belgium).

## Summary & Discussion

For elderly patients, and surely for high hyperopes, manipulating the lens can be quite challenging. This case shows that a fair amount of persistence in scleral lens fitting sometimes is needed and can pay off. The help of family members with lens handling can be of pivotal importance for the success of scleral lens wear. In extreme cases, such as in Parkinson's patients whose hands tremor, some practitioners choose to leave the lenses on day and night to avoid handling issues, but extended wear of scleral lenses is not advised or advocated in any way as it has been very well

documented that this can cause severe stress on the cornea and its physiology. In addition, in corneal graft cases it is important, especially in older graft cases like this one, to evaluate the endothelial cell count. As a general rule practitioners are advised to be extra careful if the endothelial cell count is under 1000 cells/mm<sup>2</sup>, as corneal edema becomes a serious risk at that point despite the high Dk lens materials that are used for scleral lens fits. This patient was just above this threshold, and her corneal physiology was not altered during scleral lens wear.



discussion



# Keratoconus, crosslinking & the importance of informing patients regarding post-op vision

Cristian Mertz, Jaap van Blitterswijk, Marjolijn Bartels

Corneal crosslinking (CXL) | keratoconus | RGP

## Introduction

A patient presented with bilateral keratoconus. The vision of the right eye was poor. The left eye had sub-clinical keratoconus, but the patient was now noticing that the vision was decreasing. The ophthalmologist asked if it was possible to fit lenses for both eyes.

## Subjective & objective findings

A 28-year-old male was diagnosed with bilateral keratoconus years ago. Due to adequate vision of the left eye and the anisometropia, he had never used any lenses or spectacles. He was now noticing a slow decrease in visual acuity. The patient was healthy, used no medications and had no allergies.

### Refraction:

VOD	S -10.00 C -3.00 @ 2	VA 0.5
VOS	S -0.50	VA 0.55

● **Corneal topography:** see Microlens topographer images OD and OS (with keratometric values overlay in mm).

● **Slit lamp:** examination revealed keratoconus ODS with clear corneas.

Given the corneal topography images, a scleral lens fit was suggested for the right eye, while an RGP lens was considered for the left eye. The surface area OD that exhibited an ectasia was much larger OD than OS, making it much harder to fit a regular RGP lens OD.

The first lenses ordered and dispensed after first inspection and assessment were:

**Misa Full Scleral:**  
OD Vault 4.00/S -3.00/BCR 7.00/Ø 20.0/SC 13.5/LZ normal  
**Microlens Keratoconus Anatomic (Quadrant specific lens):**  
OS S -2.00/BCR 7.10/Ø 9.8

The Keratoconus Anatomic lens for the left eye had an eccentricity of 0.9 in three quadrants and was spherical in one quadrant. In this case the spherical quadrant stabilized in the inferior quadrant, which it will do in most cases because of the inferior steepening of the cornea in a keratoconic eye.

### 1st follow-up

The patient reported that the lens felt comfortable. He could wear the lenses all day long without reapplying the lenses

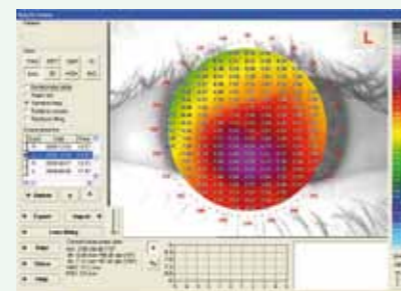
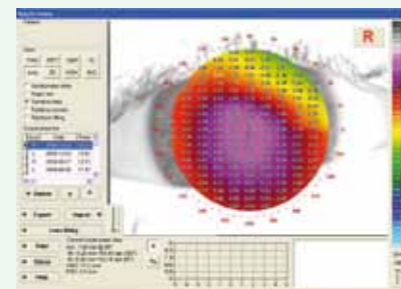
every four hours. The subjective vision was excellent. A good lens fit was evident upon slit lamp examination.

VOD	cc 0.8
VOS	cc 0.8

### Follow up after six months

The subjective binocular vision had decreased. The acuity of both eyes was 0.8 with scleral lenses and could not be improved further. There were no visible changes to the cornea. Because of the progressive nature of the keratoconus, the ophthalmologist decided to carry out a corneal crosslinking (CXL) treatment. OD was treated first, and OS followed 3 months later. Contact lenses had not been worn since 2 weeks before the procedure.

At 3 months post-op, a check-up appointment was done to evaluate the scleral lens fit, shortly after the right lens was worn again for the first time since the treatment. The right lens fit was still good, but there was an over-refraction of S -0.50, increasing the acuity from 0.70 to 0.80. The left lens was also checked 3 months after the treatment, revealing that the K values had flattened but the lens power was optimal. New contacts were ordered for OD and OS with the prescription adjusted OD and the BCR adjusted from 7.10 to 7.20 OS. A check-up was performed 3 weeks after the new lenses had been worn. The patient was very satisfied with the result, and the keratoconus appeared to have stabilized. The acuity of both eyes was sufficient, with a visual acuity of 0.80. The lenses could be worn the whole day without complaints.



## Summary & Discussion

This case shows that CXL can be an excellent treatment in progressive keratoconus, to stabilize the condition. It also demonstrates that it typically is not able to correct the keratoconus or improve vision. Patients should be made thoroughly aware of this. It is an important task of the eye care practitioner to inform the patient prior to CXL about the expected outcome. As another illustration: sometimes keratoconus patients undergoing corneal transplants

assume that all of their vision problems will be solved with the surgery. Their disappointment can be very intense and emotional when a lens is still needed after the procedure, which is often the case. It is a very important task for the eye care provider to instruct the patient about the likely need for lenses (often scleral lenses) after procedures such as CXL, corneal transplants and also intrastromal rings.

# Keratoconus, keratoplasty & acute hydrops

Jan Pauwels, Carina Koppen and Inge Leysen

Keratoconus | penetrating keratoplasty (PKP) | corneal hydrops | sagittal height

## Introduction

This case report describes a bilateral advanced keratoconus patient who, due to an acute hydrops in his left eye and an inability to wear a lens on the right eye is practically legally blind. The patient underwent a penetrating keratoplasty (PKP) 23 years ago. The transplants both exhibit excessive ectasia, which makes fitting with RGP lenses difficult. Fitting scleral lenses ODS were attempted as a solution.

## Subjective & objective findings

A 48-year-old male patient with severe keratoconus ODS, status after PKP – and an acute hydrops OS.

### Refraction:

VOD	sc	VA 0.05
VOS	sc	VA light perception

● **Corneal topography:** severe irregular corneas.

● **Slit lamp:** examination showed a clear cornea with extreme vault OD (see slit lamp images OD), and OS extreme vault with a hydrops visible inferiorly at the junction with the donor button as a milky white spot located over the pupil area (see slit lamp images OS).

A scleral lens was fitted OD at this point. A scleral lens fitting OS occurred three months later after the cornea had settled down and the hydrops looked quiet.

The lenses ordered and dispensed after first inspection and assessment were:

**Misa Full Scleral:**  
Vault 5.00 /S+2.00/BCR 8.20/Ø 20.00/SC 13.5/LZ normal  
Vault 5.25 /S-0.00/BCR 8.30/Ø 20.00/SC 13.5/LZ normal

### Over-refraction:

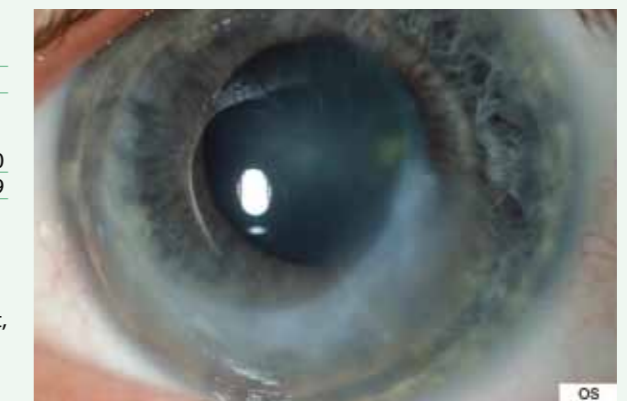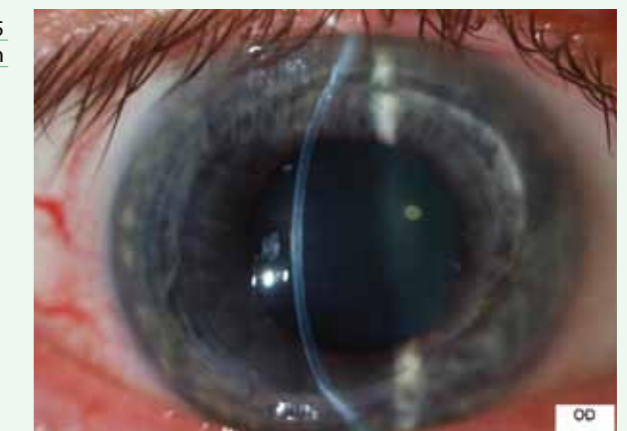
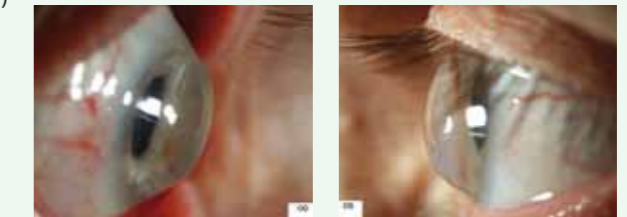
VOD	S 0.00	VA 1.0
VOS	S 0.00	VA 0.9

### 1st follow up visit

Because of the extreme ectasia, the right eye was fitted with a scleral lens with a vault of 500. The visual acuity with this lens proved to be outstanding and, despite the extreme vault, the lens was worn comfortably, too. For the left eye, once the cornea had settled, an exceptionally good VA was also reached.

## 2nd follow up visit

After six months, these lenses with extreme vault were still worn comfortably and with exceptionally good visual acuities.



© Photographs: University Hospital Antwerp (Belgium).

## Summary & Discussion

One complication of keratoconus and other ectatic disorders is acute hydrops. Descemet's membrane ruptures, and the stroma and epithelium become edematous from the resulting inflow of aqueous. The symptoms can include blurry vision, pain, photophobia, excessive tearing and complaints of a "white spot" on the eye. Over time, the endothelial cells migrate, enlarge and pump out the edema. Once the hydrops has resolved, scleral lens wear may resume with sometimes surprising results.

Acute hydrops can be very dramatic to a clinician and even more frightening to a patient. Hydrops is known to resolve

on its own, but the epithelial edema may worsen from wearing a scleral lens. Once the edema resolves, the patient can resume scleral lens wear. Sometimes the refraction may have changed as a result of the corneal flattening, which also may have significant effects on higher-order aberrations. The dense scar may mislead clinicians to refer affected patients for a transplant, but exploring all refractive options, including scleral lenses, may render surgery unnecessary.

Source: Lynette Johns – I-site case report October 2011 (www-i-sitenewsletter.com)



This publication has been initiated and made possible by Microlens Contactlens Technology, b.v. in the Netherlands. Microlens is a leading company in the development and production of specialty lenses. For the last decades Microlens has played a major role in the development of aspheric GP's, new generations of prescription soft lenses and in the last years also in the development of scleral lenses, mini scleral lenses and corneo-scleral lenses.

The purpose of this publication is to explain all the possibilities that this new generation of scleral lenses offers as well as to provide a realistic view of the field of indications. Part 2 of this publication is now available. It fully focuses on the actual fitting of the lenses. It provides a complete description of the fitting procedure in a logical way. It is a fitting manual of the Misa® scleral and mini scleral lenses. In combination with our hands-on seminar this document enables practitioners to fit these lenses on their patients themselves. They will get accustomed to the procedure very quickly and learn to fit those lenses in a clear and organized way at a very high success rate.

The fitting procedures described in this book are all done with the latest generation of Misa® scleral and mini lenses, developed and manufactured by Microlens.

MICROLENS

## Microlens: the scleral lens reinvented



Due to a new and innovative design principle of the Misa® scleral and mini scleral lenses the number of possible applications could be raised considerably.

### The advantages for the patient are:

- The wearing comfort is much higher than that of the traditional designs of scleral lenses.
- The lenses are much easier to handle due to their size: The diameter of the Misa® scleral lens is approx. 20 mm and the diameter of the Misa® mini scleral lens is approx. 16.5 mm.

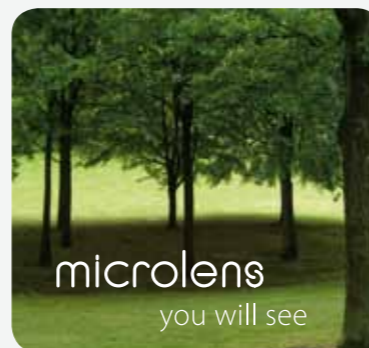• Last not least, these new lenses are not deterrent like the traditional much larger scleral lenses often are due to their size.

### The advantages for the fitter are:

- The entire fitting procedure is logical, clear and predictable. That makes these lenses often the first choice to correct the pathological eye.
- The countless varieties within the system offer now solutions for eyes that were impossible to correct earlier.



Microlens is located in the beautiful Arnhem Business Park, a former country estate situated on the border of a lateral moraine and the River Rhine.



## Training

Until now the fitting of scleral lenses has been reserved for only a few practitioners with years of experience in order to have a reasonable or good percentage of success. With the introduction of the Misa® lens system in 2009 the threshold for the application as well as the fitting of the lenses has been lowered tremendously. That is the reason why in the meantime thousands of patients are successfully equipped with these lenses, and now enjoy a big improvement in their quality of life.

If you work in the contact lens environment where you often see those patients, we would love to teach you the application of the Misa® lenses. For that reason we have produced the manual "Misa Lens Scleral Lens Fitting" and we would like to give you the hands on training:

### There are several options to reach that goal:

- Microlens organizes two days weekend seminars on regular bases in our Training Department in Arnhem, the Netherlands. We can offer you a complete arrangement. If you are interested, please contact us for dates etc. at (info@microlens.nl)
- We can also organize seminars for small groups at your premises. For more information, Please contact us by mail, telephone or letter.



**Microlens Contactlens Technology b.v.**  
Utrechtseweg 310, building B12  
NL-6812 AR Arnhem, The Netherlands  
Phone +31 26 354 44 44, fax +31 26 354 44 35

The seminars are held in English.

## Misa lenses: full scleral lenses and mini scleral lenses

Although the possibilities and varieties in the Misa® lens system are enormous, we offer a trial set of 19 trial lenses that supplies you with almost unrestricted fitting possibilities.

In those rare cases where you do need different specifications, we can provide additional trial lenses.



YOU WILL SEE

### The Misa Lens Trial Set

#### MISA Mini Lens

- Lower grade of Keratoconus
- Corneal degenerations and dystrophies
- High refractive errors or astigmatism
- Ptosis
- Trichiasis

#### MISA Scleral Lens

- All higher grades of Keratoconus, Keratoglobus, Pellucid Marginal Degeneration
- Post surgery: corneal transplants
- Traumas
- Dry eye management, Stevens Johnson syndrome, Sjogren syndrome
- Contact and water sport

#### MISA Mini (flat radii)

- Post surgery: Lasik, Lasek, PRK and RK

#### MISA Non rotational symmetric lens

- For optimizing and evaluation of the fit on a toric sclera



notes

A large, light green rectangular area with rounded corners, containing numerous horizontal lines for writing. This area is intended for taking notes.